

* Corresponding author.

E-mail: ingmeireles@hotmail.com (I.R. Holanda).

Received 25 October 2022; accepted 16 February 2023

Available online 23 September 2023

<https://doi.org/10.1016/j.abd.2023.02.008>

0365-0596/ © 2023 Sociedade Brasileira de Dermatologia.

Published by Elsevier España, S.L.U. This is an open access article under the CC BY license (<http://creativecommons.org/licenses/by/4.0/>).

Mycobacterium abscessus* sporotrichoid infection after a dog bite



Dear Editor,

The terms “atypical mycobacteria” or “non-tuberculous mycobacteria” (NTM) refer to a group of mycobacteria other than *Mycobacterium tuberculosis* and *Mycobacterium leprae*.^{1,2} NTM are ubiquitous organisms that can resist extreme temperature conditions.^{1,2} *M. abscessus* is a fast-growing atypical mycobacterium that can cause cutaneous lesions and disseminated infections, typically after skin trauma.² Dermatological manifestations include nodules, abscesses, and ulcers that may often resemble *Sporothrix* infections.¹ Zoonotic transmission is rarely reported.³

Case report

A 63-year-old female presented with a history of a 2-month enlarging nodule over the medial aspect of the thigh after suffering a street dog bite. She was previously treated with clindamycin 300 mg TID for 21 days without improvement. On examination, there were 3 ulcerated, purulent gummas over an erythematous, warm, tender, fluctuating area of the thigh (Fig. 1). No adenomegalies were found. Samples were taken from the secretion for microbiological and molecular biology studies. Gram stain, KOH smear, and Sabouraud culture were negative. Acid-fast bacilli were identified on the Ziehl-Nielsen stain (Fig. 2). Creamy, white, cerebriform colonies grew on Lowenstein Jensen culture (Fig. 3) and with the identification of 1) PCR-RFLP (polymerase chain reaction-restriction fragment length polymorphism) of the *gyrB* and *hsp65* genes with the digestion of the *RsaI*, *TaqI* or *Sac II* enzymes and *HhaI* enzyme respectively and 2) Multi-primer PCR to detect the absence or the presence of the RD9 and RD1 regions confirmed *M. abscessus*. The patient received amikacin 1 g IM daily for 2 weeks in two cycles plus clarithromycin 500 mg BID for 4 months, showing a favorable clinical response (Fig. 4).

NTM comprise a heterogenous group of acid-fast bacilli that are further classified according to their growth speed, morphology, and pigmentation.¹ They were first described in 1931 by Pinnors, and there are now more than 200 reported species.³ *M. abscessus* is associated with a wide spectrum of dermatological lesions that include cellulitis, abscesses,

papules, pustules, fistulae, ulcers, necrotic lesions, and subcutaneous nodules that can resemble *Sporothrix* lesions.^{2,3}

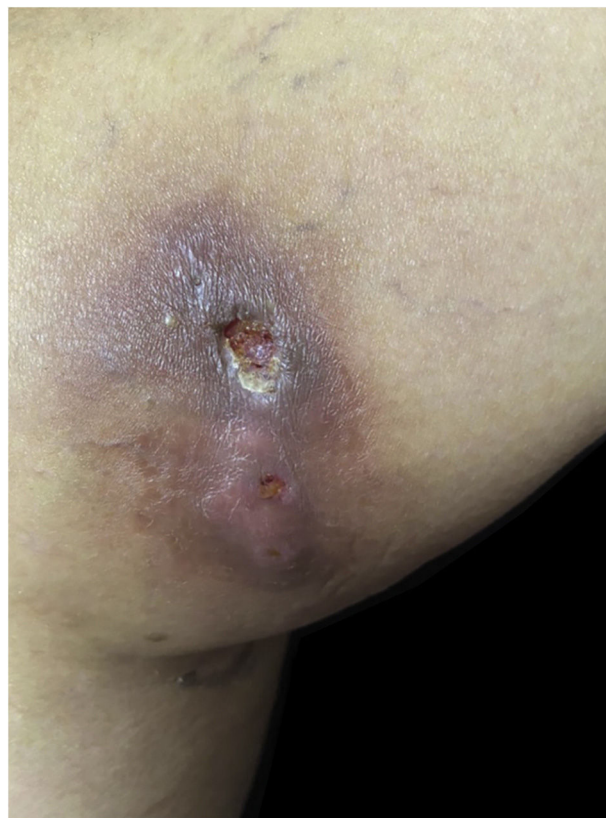

Figure 1 Three ulcerated, purulent, gummas affecting the thigh

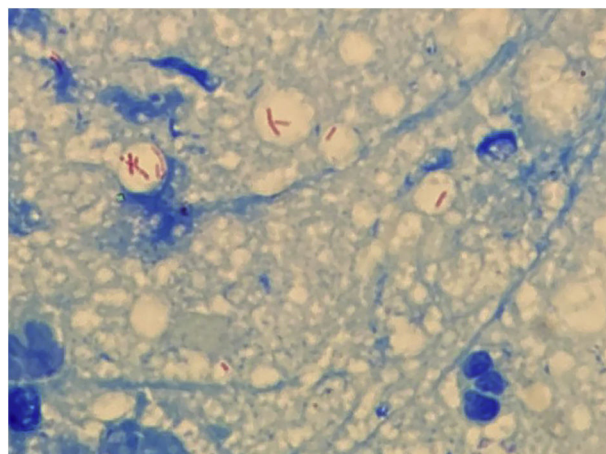
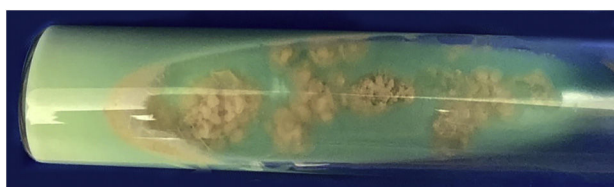


Figure 2 Abundant acid-fast bacilli can be observed with Ziehl-Neelsen stain

* Study conducted at the Dermatological Institute of Jalisco “Dr. José Barba Rubio”, Secretariat of Salud Jalisco, Zapopan, Jalisco, México.

Table 1 Cases of non-tuberculous mycobacteria infection after dog bites in humans and canines

Author; year	Host	Comorbidity	Affected area	Type of infection	Agent
Ariel et al; 1983. ⁵	Male, 55 years old	None	Hand	Granulomatous synovitis	<i>Mycobacterium fortuitum</i>
Southern; 2004 ⁶	Male, 68 years old	Diabetes mellitus type 2	Hand	Tenosinovitis	<i>Mycobacterium kansasii</i>
Minato et. al., 2021 ⁷	Male, 77 years old	None	Hand	Tenosinovitis	<i>Mycobacterium chelonae</i>
Fox et al., 1995 ⁸	Canine, male, 15 months old	None	Neck and trunk	Subcutaneous infection	<i>Mycobacterium fortuitum</i>
Malik et al., 2004 ⁹	Canine, female, 4 years old	Obese	Neck	Pyoderma panicullitis	<i>Mycobacterium smegmatis</i>
Malik et al. 2004 ⁹	Canine, female, 5 years old	Obese	Trunk	Pyoderma	<i>Mycobacterium smegmatis</i>

**Figure 3** *M. abscessus* colonies grew in Lowenstein Jensen culture after 7 days

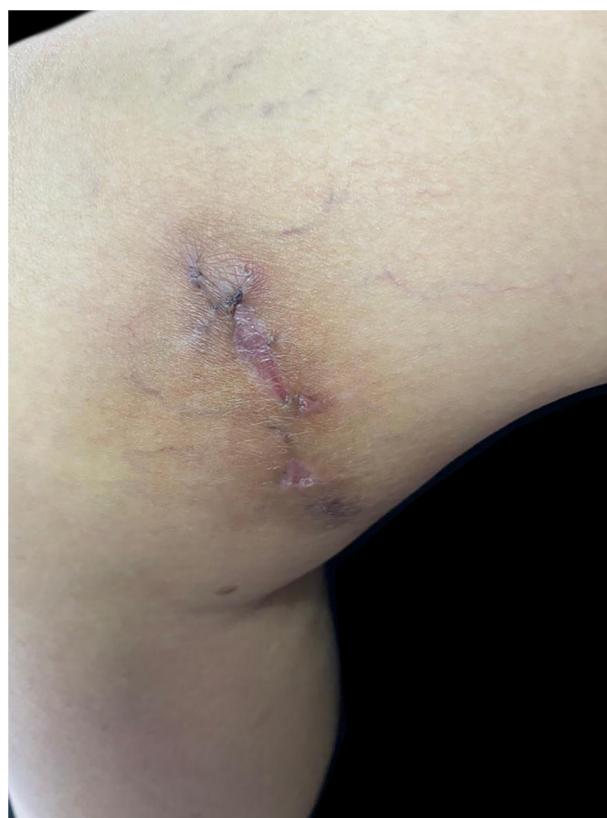Wounds by animal bites are typically caused by domestic dogs, which harbor a diverse oral microbiota that includes facultative and obligate anaerobes. Such diversity depends on the age, feeding, and oral health of the canine, among other factors.⁴ There are scant reports of zoonotic transmission of NTM infection after canine bites in both humans⁵⁻⁷ and dogs^{8,9} (Table 1).⁵⁻⁹ In humans, only the upper extremity has been reported to be affected with either *M. fortuitum*, *M. kansasii*, or *M. chelonae*. In canines, only *M. fortuitum* and *M. smegmatis* infection have been documented. To the best of our knowledge, *M. abscessus* transmission has not been previously reported.

The diagnosis of NTM infection includes direct microscopy, culture in a selective medium, biochemical testing, chromatography, and molecular biology techniques; the latter being the preferred method.¹⁰

Unfortunately, the treatment is not well established. However, antibiotic combination therapy and surgical drainage of the lesions is strongly recommended.^{1,3} The choice of antibiotics usually involves clarithromycin or azithromycin plus amikacin, cefoxitin, or imipenem for severe infections. Treatment duration may span from 3 to 6 months. There are no clinical studies that compare different treatment schemes.²

Conclusion

Among all infectious agents that may cause disease after a canine bite, NTM is some of the most therapeutically challenging. The oral cavity of dogs may be colonized by NTM as a commensal pathogen and canines should therefore be considered a possible vector. Since the clinical presentation of sporotrichosis may be undistinguishable from NTM lesions,

**Figure 4** Favorable clinical response

we emphasize the need to run all appropriate microbiological tests available that include acid-fast bacilli detection, apart from ordinary smears and cultures.

Financial support

None declared.

Authors' contributions

Patricia Guadalupe Mendoza-Del Toro: Critical literature review, preparation and writing of the manuscript.

Arturo Robles-Tenorio: Manuscript critical review, intellectual participation in propaedeutic and/or therapeutic management of studied cases.

Víctor Manuel Tarango-Martínez: Critical literature review, intellectual participation in propaedeutic and/or therapeutic management of studied cases, approval of the final version of the manuscript.

Conflicts of interest




None declared.

References

1. Kalpana T, Mugunthan M, Joseph NM, Kalaiarasan E. A comprehensive review and update on epidemiology, symptomatology and management of nontuberculous mycobacteria (NTM). *J Pure Appl Microbiol.* 2022;16:814–24.
2. Nogueira LB, Garcia CN, Costa MSC, Moraes MB, Kurizky PS, Gomes CM. Non-tuberculous cutaneous mycobacterioses. *An Bras Dermatol.* 2021;96:527–38.
3. Gardini G, Gregori N, Matteelli A, Castelli F. Mycobacterial skin infection. *Curr Opin Infect Dis.* 2022;35:79–87.
4. Zhang L, Li Y, Yang H, Mu Y, Jiang J, Duan X. Mycobacterium chelonae infection after a cat bite: a rare case report. *Clin Cosmet Investig Dermatol.* 2022;15:1847–51.
5. Ariel I, Haas H, Weinberg H, Rousso M, Rosenmann E, Israel J. Mycobacterium fortuitum granulomatous synovitis caused by a dog bite. *J Hand Surg.* 1983;8:342–5.
6. Southern PM Jr. Tenosynovitis Caused by Mycobacterium kansasii associated with a dog bite. *Am J Med Sci.* 2004;327:258–61.
7. Minato S, Sukegawa K, Onuma K, Otake Y, Iida R, Takaso M. Polymicrobial extensor tenosynovitis including mycobacterium

chelonae caused by a dog bite: a case report. *JBS Case Connect.* 2021;11, e20.00608.

8. Fox LE, Kunkle GA, Homer BL, Manella C, Thompson JP. Disseminated subcutaneous Mycobacterium fortuitum infection in a dog. *J Am Vet Med Assoc.* 1995;206:53–5.
9. Malik R, Shaw SE, Griffin C, Stanley B, Burrows AK, Bryden SL, et al. Infections of the subcutis and skin of dogs caused by rapidly growing mycobacteria. *J Small Anim Pract.* 2004;45:485–94.
10. García-Martos P, García-Agudo L. Infections due to rapidly growing mycobacteria. *Enferm Infecc Microbiol Clin.* 2012;30:192–200.

Patricia Guadalupe Mendoza-Del Toro (Patricia) (MD) ^{a,*}, Arturo Robles-Tenorio (Arturo) (MD) ^b, Víctor Manuel Tarango-Martínez (Victor) (MD) ^a

^a *Department of Dermatology, Dermatological Institute of Jalisco “Dr. José Barba Rubio”, Secretariat of Salud Jalisco, Zapopan, Jalisco, Mexico*

^b *Department of Dermatology, Faculty of Medicine and Health Sciences, Tecnológico de Monterrey, Monterrey, Mexico*

* Corresponding author.

E-mail: patricia_2495@outlook.com (P.G. Mendoza-Del Toro (Patricia)), arturo.rt@tec.mx (A. Robles-Tenorio (Arturo)), drtarangovic@gmail.com (V.M. Tarango-Martínez (Victor)).

Received 12 December 2022; accepted 1 February 2023

Available online 27 September 2023

<https://doi.org/10.1016/j.abd.2023.02.004>

0365-0596/ © 2023 Sociedade Brasileira de Dermatologia.

Published by Elsevier España, S.L.U. This is an open access article under the CC BY license (<http://creativecommons.org/licenses/by/4.0/>).