

Anderson et al.<sup>4</sup> analyzed the ingredients of 48 slime recipes available on the internet and demonstrated that the most common were fragrance mix I and II, and preservatives such as propylene glycol and MI (the positive allergen in our patient's patch test).<sup>4</sup>

Clinically, the causes of hand dermatitis may be indistinguishable. Patch test is essential, not only for differential diagnosis (ICD and ACD), but also to detect the causative allergen. It is important to identify it, as these substances are also part of patient's everyday products, such as shampoos, soaps and creams. Thus, if there is no precise diagnosis, dermatitis can evolve with relapses, increasing morbidity and making it difficult to control the disease.

### Financial support

None declared.

### Authors' contributions

Nabila Scabine Pessotti: Elaboration and writing of the manuscript; critical review of the literature.

Mariana de Figueiredo Silva Hafner: Approval of the final version of the manuscript; elaboration and writing of the manuscript; intellectual participation in the propaedeutic and/or therapeutic conduct of the studied cases.

Mellanie Starck Possa: Approval of the final version of the manuscript; elaboration and writing of the manuscript; intellectual participation in the propaedeutic and/or therapeutic conduct of the studied cases.





Rosana Lazzarini: Approval of the final version of the manuscript; conception and planning of the study; effective participation in research orientation; intellectual participation in the propaedeutic and/or therapeutic conduct of the studied cases.

### Conflicts of interest

None declared.

### References

1. Asher C, Dalan R, Aly MI. Home-made Slime<sup>TM</sup>: a novel cause for pediatric burns' referrals; do we need to raise awareness? *Burns*. 2018;44:1613.
2. Heller E, Murthy AS, Jen MV. A slime of the times: two cases of acute irritant contact dermatitis from homemade Slime. *Pediatr Dermatol*. 2019;36:139–41.
3. Piazza CD, Cestari SCP. Contact dermatitis from do-it-yourself slime. *An Bras Dermatol*. 2018;93:944.
4. Anderson LE, Treat JR, Brod BA, Yu J. "Slime" contact dermatitis: case report and review of relevant allergens. *Pediatr Dermatol*. 2019;36:335–7.

Nabila Scabine Pessotti <sup>a</sup>,  
Mariana de Figueiredo Silva Hafner <sup>a</sup>,  
Mellanie Starck Possa <sup>b</sup>, Rosana Lazzarini <sup>a,\*</sup>

<sup>a</sup> *Skin Allergy Sector, Department of Medicine, Dermatology Clinic, Santa Casa de Misericórdia de São Paulo, São Paulo, SP, Brazil*

<sup>b</sup> *Improvement Course of Skin Allergies, Dermatology Clinic, Santa Casa de Misericórdia de São Paulo, São Paulo, SP, Brazil*

\* Corresponding author.

E-mail: [rosana.fototerapia@gmail.com](mailto:rosana.fototerapia@gmail.com) (R. Lazzarini).

Received 24 April 2019; accepted 9 June 2019;  
Available online 15 February 2020

<https://doi.org/10.1016/j.abd.2019.06.008>

0365-0596/ © 2020 Sociedade Brasileira de Dermatologia.

Published by Elsevier España, S.L.U. This is an open access article under the CC BY license (<http://creativecommons.org/licenses/by/4.0/>).

## Onychomadesis secondary to hand-foot-and-mouth disease: report of two cases<sup>☆,☆☆</sup>



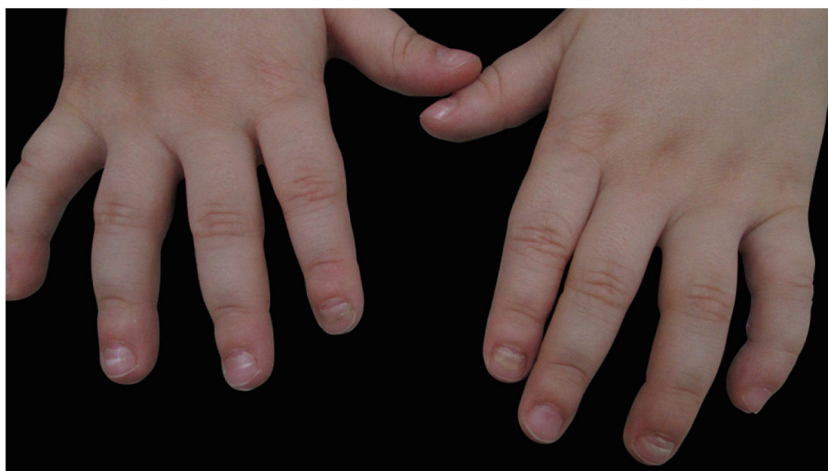
Dear Editor,

Although onychomadesis secondary to hand-foot-and-mouth disease (HFM) is an uncommon clinical manifestation; it threatens parents and child caregivers. In a case series of 145 Thai patients, it occurred in 5–37% of cases, depending on the virus.<sup>1</sup> HFM is more frequently caused by coxsackie virus, subtype A6, but some enterovirus and echovirus may also be involved. It is common in children below 10 years of

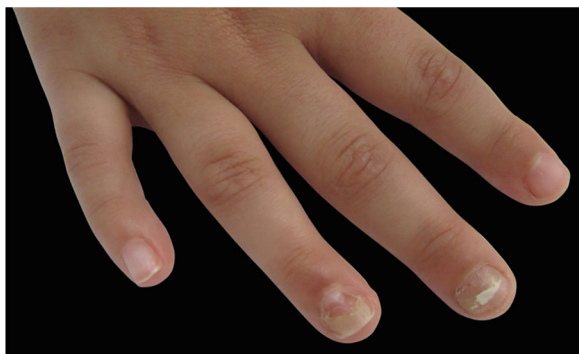age,<sup>2</sup> and manifests with flu-like symptoms (fever, lymphadenomegaly, dizziness, vomiting and discomfort) associated to canker sores in the oral mucosae and bullae on the hands and feet. Oral-faecal transmission for 30 after the resolution of symptoms and skin lesions. Nail changes often observed in HFM are Beau lines, leukonychia, and onychomadesis.<sup>3</sup> Beau lines are white transverse grooves, resulting from temporary stop in nail plate formation.<sup>3</sup> Onychomadesis may be a more severe form of this commitment, when nail growth is interrupted for one or two weeks, resulting in detachment of the nail plate from nail bed. The new nail grows without connection to the older one, leading to splitting and detachment of the older nail. It has been proposed that this alteration may be caused by toxic direct action of the virus in the matrix or by the inflammation secondary to maceration of digital bullae.<sup>4</sup> According to a case series,<sup>1</sup> onychomadesis is more usual in HFM caused by Coxsackie A6 virus than other viruses. Nevertheless, a Spanish study,<sup>5</sup> which investigated an onychomadesis outbreak (311 cases) showed high frequency of HFM as a possible cause (60%), a fingering confirmed by identifying coxsackie and enterovirus in faecal

<sup>☆</sup> How to cite this article: Ocanha-Xavier JP, Xavier Jr JCC. Onychomadesis secondary to hand-foot-and-mouth disease: report of two cases. *An Bras Dermatol*. 2020;95:272–3.

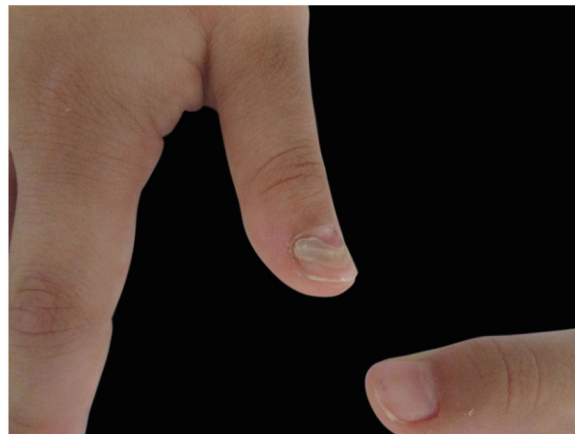<sup>☆☆</sup> Study conducted at the Private Clinic Tiradentes, Vila Mendonça Araçatuba, SP, Brazil.



**Figure 1** Hands from patient with 3 years old, showing Beau lines in almost every nail, and onychomadesis in second (both sides) and fourth finger.



**Figure 2** Right hand from the 7-year-old showing onychomadesis in third and fourth fingers.



**Figure 3** Details from first finger of the right hand from the 7-year-old patient, showing detachment of the previous nail from the newer one.

samples<sup>5</sup> Obs. adicionar referencia subscrito. Treatment is symptomatic because it is a self-limited disease with rare sequelae. We present a 3-year-old male patient (Fig. 1) and a 7-year-old female patient (Figs. 2 and 3) with onychomadesis secondary to HFM, with history of flu-like symptoms, followed up by oral and acral lesions. Nail changes appeared around 14 days after the symptoms began in the first case and 10 days in the second one. They had complete resolution of the nail alterations, with no specific treatment and no sequelae. Parent counselling about this manifestation is necessary to avoid untimely therapeutics and unnecessary emergency consultations.

### Financial support

None declared.

### Authors' contributions

Juliana Polizel Ocanha Xavier: Approval of the final version of the manuscript; conception and planning of the study; elaboration and writing of the manuscript; obtaining, analysis, and interpretation of the data; effective participation in research orientation; intellectual participation in

the propaedeutic and/or therapeutic conduct of the studied cases; critical review of the literature; critical review of the manuscript.

José Cândido Caldeira Xavier Junior: Approval of the final version of the manuscript; critical review of the literature; critical review of the manuscript.



### Conflicts of interest

None declared.

### References

1. Wei SH, Huang YP, Liu MC, Tsou TP, Lin HC, Lin TL, et al. An outbreak of coxsackievirus A6 hand, foot, and mouth disease associated with onychomadesis in Taiwan, 2010. *BMC Infect Dis.* 2011;11:346.
2. Kimmis BD, Downing C, Tyring S. Hand-foot-and-mouth disease caused by coxsackievirus A6 on the rise. *Cutis.* 2018;102:353–6.

- Mortada I, Mortada R, Bazzal MA. Onychomadesis in a 9-month-old boy with hand-foot-mouth disease. *Int J Emerg Med.* 2017;10:26.
- Akpolat ND, Karaca N. Nail changes secondary to hand-foot-mouth disease. *Turk J Pediatr.* 2016;58:287–90.
- Davia JL, Bel PH, Ninet VZ, Bracho MA, Candelas FG, Salazar A, et al. Onychomadesis outbreak in Valencia, Spain associated with hand foot, and mouth disease caused by enteroviruses. *Pediatr Dermatol.* 2011;28:1–5.

Juliana Polizel Ocanha Xavier  <sup>a,\*</sup>,  
José Cândido Caldeira Xavier Junior  <sup>b</sup>

<sup>a</sup> Faculdade de Medicina de Botucatu, Universidade Estadual Paulista, Botucatu, SP, Brazil

<sup>b</sup> Faculdade de Medicina, Centro Universitário Católico Salesiano Auxilium, Unisalesiano, Araçatuba, SP, Brazil

\* Corresponding author.

E-mail: [jpocanha@gmail.com](mailto:jpocanha@gmail.com) (J.P. Xavier).

Received 5 March 2019; accepted 13 June 2019;  
Available online 20 February 2020

<https://doi.org/10.1016/j.abd.2019.06.011>

0365-0596/ Published by Elsevier España, S.L.U. on behalf of Sociedade Brasileira de Dermatologia. This is an open access article under the CC BY license (<http://creativecommons.org/licenses/by/4.0/>).

## Idiopathic follicular mucinosis in childhood

Dear Editor,

Follicular mucinosis is a rare condition, belonging to the group of cutaneous mucinoses, characterized by localized or diffuse mucin deposits in the skin or within hair follicles. Two forms were described: primary (or idiopathic) and secondary form, which may be associated with benign or malignant conditions.<sup>1</sup>

The presence of well-defined papular, erythematous or reddish-brown erythema papules or plaques clinically characterize the condition. Follicular keratosis or alopecic patches could also be observed. Other less common forms have been described, such as acneiform, eczematous, cystic or nodular.<sup>2</sup>

The patient is an 11-year-old white male, with no relevant personal or family history, with a 2 year history of asymptomatic cutaneous lesion on the face.

On the dermatological examination: hypochromic lesion topped by follicular and nonfollicular shiny papules on the nasal, malar, zygomatic and left periorbital region and papular lesions on the upper right eyelid and mild left eyelid edema (Fig. 1). Sensory evaluation results are normal.

A routine anatomopathological examination (Hematoxylin & eosin staining) reveals preserved epidermis. Dermis presents some hair follicles containing fibromyxoid stroma and mixed pattern inflammatory cells (Fig. 2). Alcian Blue stain reveals built-up mucin in the outer root sheath of the hair follicle (Fig. 3).

Laboratory tests were requested to investigate associated diseases; all results were normal.

Treatment with daily application of high-potency topical corticosteroid showed improvement; however, recurrence occurred when discontinued.

In 1957, Hermann Pinkus described a group of 6 patients with localized alopecia, histopathologically characterized

by mucin deposits in the hair follicles, which he named alopecia mucinosa. Jablonska et al. proposed in 1959 to change the name to follicular mucinosis, a term accepted to this day.<sup>3</sup>

Its cause is still unknown. Today, it is considered a standard reaction of the follicular epithelium to various factors.<sup>1</sup>

This dermatosis can have two clinical forms:<sup>1,2,4</sup>

- Primary form: an idiopathic, benign and transient form, which commonly occurs in children and adults. In younger patients, it usually affects the head and neck, receding spontaneously after 2–24 months in most cases. Some rare cases of developing Hodgkin's disease, other lymphomas and leukemia have been recorded. Adult patients present generalized lesions that may last indefinitely.<sup>4</sup>

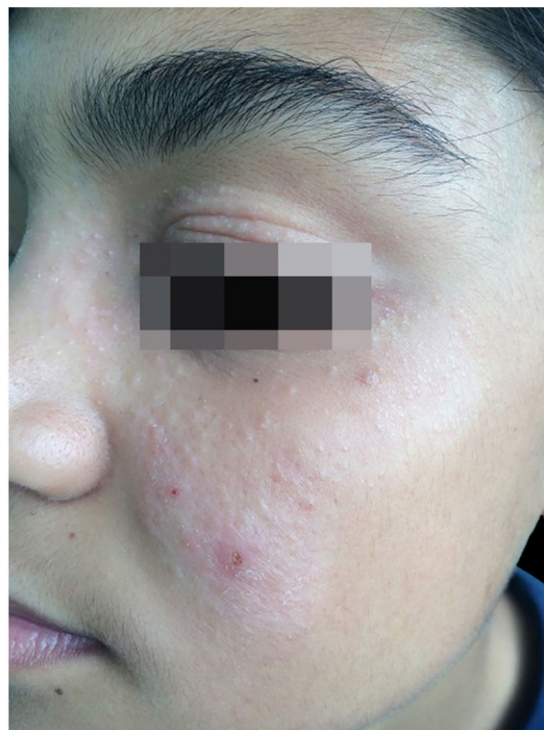


Figure 1 Hypochromic lesion topped by shiny papules.

☆ How to cite this article: Bauer FJ, Almeida JRP, Sementilli A, Mattos e Dinato SL. Idiopathic follicular mucinosis in childhood. *An Bras Dermatol.* 2020;95:274–6.

☆☆ Study conducted at the Hospital Guilherme Álvaro, Santos, SP, Brazil.