





Wen-Ju Wang: Approval of the final version of the manuscript; conception and planning of the study; effective participation in research orientation.

Conflicts of interest

None declared.

References

1. Salah H, Urso B, Khachemoune A. Review of the etiopathogenesis and management options of chondrodermatitis nodularis chronica helioides. *Cureus*. 2018;10:e2367.
2. Sasaki T, Nishizawa H, Sugita Y. Chondrodermatitis nodularis helioides in childhood dermatomyositis. *Br J Dermatol*. 1999;141:363–5.
3. Rogers NE, Farris PK, Wang AR. Juvenile chondrodermatitis nodularis helioides: a case report and literature review. *Pediatr Dermatol*. 2003;20:488–90.
4. Magro CM, Frambach GE, Crowson AN. Chondrodermatitis nodularis helioides as a marker of internal disease [corrected] associated with microvascular injury. *J Cutan Pathol*. 2005;32:329–33.
5. Grigoryants V, Qureshi H, Patterson JW, Lin KY. Pediatric chondrodermatitis nodularis helioides. *J Craniofac Surg*. 2007;18:228–31.

Li-Wen Zhang *,¹, Lin Li ¹, Cong-Hui Li ,
Wen-Ju Wang 

Department of Dermatovenereology, Chengdu Second People's Hospital, Chengdu, Sichuan, China

* Corresponding author.

E-mail: zhleven@126.com (L. Zhang).

¹ Contributed equally to this work.

Received 27 March 2019; accepted 20 June 2019

Available online 19 March 2020

<https://doi.org/10.1016/j.abd.2019.06.014>

0365-0596/ © 2020 Sociedade Brasileira de Dermatologia.

Published by Elsevier España, S.L.U. This is an open access article under the CC BY license (<http://creativecommons.org/licenses/by/4.0/>).

Cutaneous and pulmonary cryptococcosis^{☆,☆☆}



Dear Editor,

Cryptococcus neoformans is the etiological agent of cryptococcosis, an infectious disease that affects humans, domestic and wild animals. This pathogen is often found in pigeon excreta, possessing innumerable environmental sources.¹

The diagnosis can be performed by analysis of cerebrospinal fluid (CSF), urine sediment, bronchoalveolar lavage fluid, wound exudates, floating node aspirate and suspected lesions biopsies.²

Treatment of cryptococcosis in immunocompetent and immunocompromised humans, consists of amphotericin B in combination with 5-flucitosin in disseminated infections; or with fluconazole or itraconazole, as an alternative for the treatment of cutaneous infections.³

A 36-year-old female patient presented an ulcerated plaque with hematic crust and erythematous infiltrated edges topped with pustules, measuring approximately 3 cm length in the posterior region of the left ear (Fig. 1). The patient related the lesion appeared 4 months before the appointment, accompanied by systemic symptoms such as intermittent fever, productive cough, and weight loss of approximately 5 kg in 15 days. Chest X-ray showed evidence of hypotransparency in the middle segment of the right lung lobe. Patient was insulin-dependent diabetic and had

a history of kidney transplant performed three years ago and in use of azathioprine and prednisone. After dermatological evaluation, it was decided to perform lesional skin scrapings and mycological culture of the lesion's secretion

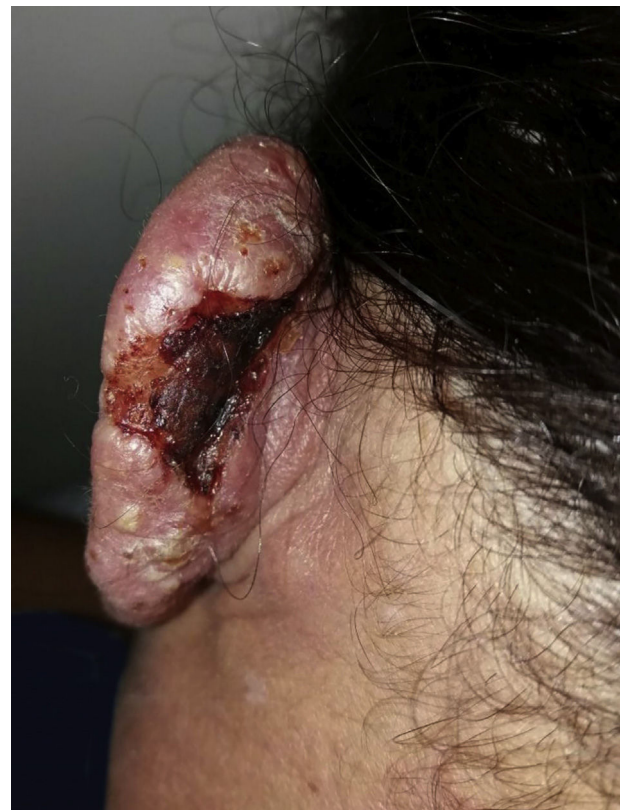

Figure 1 Cutaneous lesion in the posterior region of the left ear.

[☆] How to cite this article: Markman DL, Oliveira PPB, Takano DM, Cambuim IIFM. Cutaneous and pulmonary cryptococcosis. *An Bras Dermatol*. 2020;95:394–6.

^{☆☆} Study conducted at the Department of Dermatology of Hospital Otávio de Freitas, Recife, PE, Brazil.

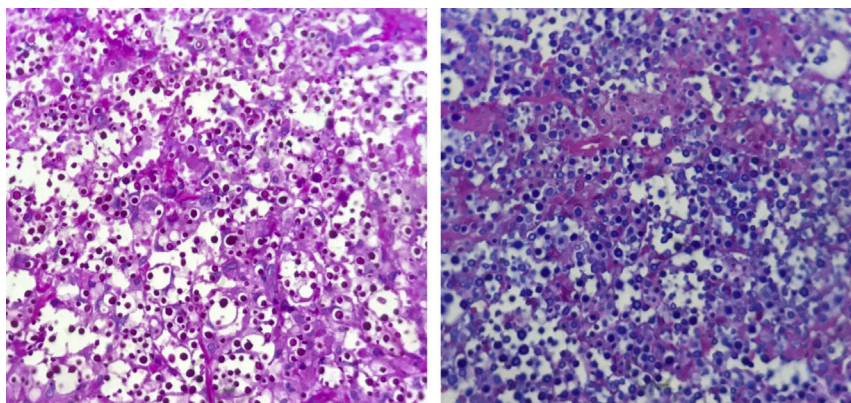


Figure 2 Histopathology. PAS (left) and Alcian blue (right) staining of cryptococci, $\times 400$.

and the sputum, as well as an incisional biopsy, with the removal of two fragments for mycological and histopathological study. Slides of direct secretion and sputum were prepared with addition of India ink upon which capsulated yeasts were observed. In the mycological culture of all the samples, there was a development of colonies of white to cream color of mucous aspect typical of *Cryptococcus* spp. The species identification and antifungal susceptibility were performed in the Vitek 2-Compact. The isolate was also identified by sequencing the D1/D2 domain of the rDNA using the primers NL1 and NL4 being identified as *Cryptococcus neoformans* (San Felice) Vuill (1901). Histopathology revealed numerous yeast fungal structures, best visualized by PAS staining (periodic acid-Schiff), with mucopolysaccharides capsules that stand out for Alcian Blue staining, with scarce inflammatory infiltrate in between (Fig. 2). The patient was hospitalized and treated with amphotericin B associated with fluconazole. After significant clinical improvement, the patient was discharged on the use of fluconazole daily until complete resolution of the cutaneous condition (Fig. 3).

According to literature, this mycosis is commonly diagnosed in patients with cellular immunosuppression, such as HIV positive, being the most frequent systemic mycosis in this group of patients and the third cause of opportunistic Central Nervous System (CNS) disease.^{1,4} In renal transplant patients, cryptococcosis occurs in 0.8–5% of them, depending on the type and intensity of immunosuppression.⁵ Infection is usually observed in the late postoperative period, about four months after the introduction of immunosuppressive drugs.⁵

Drug resistance, when using fluconazole, is likely to occur during prolonged suppressive treatments as in cases of *C. neoformans* meningitis.¹ For the treatment of renal transplant patients using immunosuppressive drugs, drug interactions and side effects should be especially considered, particularly the intrinsic nephrotoxicity of amphotericin B.⁵ There is still no consensus regarding dose adjustment, time and duration of treatment, as well as the need of maintenance therapy.⁵

This report presents the medical history of a patient with cutaneous and pulmonary alterations, which allowed the

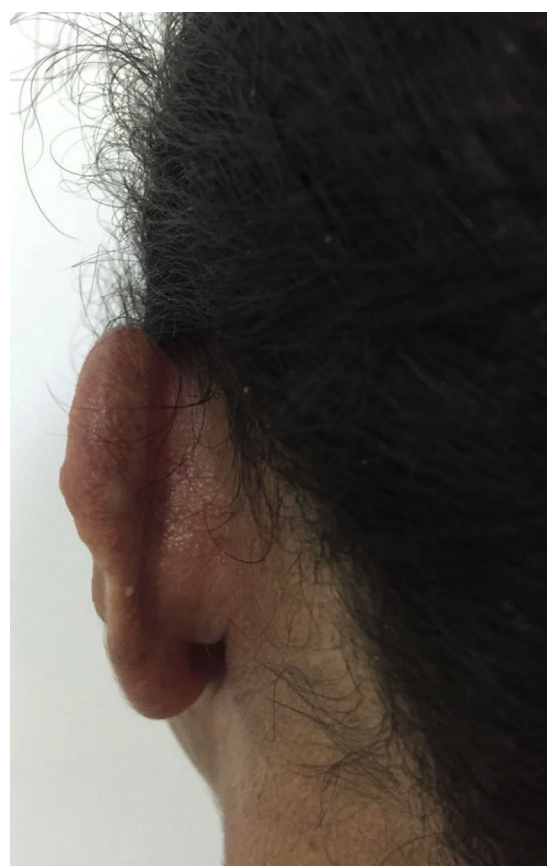

Figure 3 Post-treatment cutaneous lesion.

diagnosis of cryptococcosis and the appropriate treatment for it. Through this report we could highlight the importance of the differential diagnosis of infectious conditions in renal transplant patients.

Financial support

None declared.

Authors' contributions

Deborah Lucena Markman: approval of the final version of the manuscript; elaboration and writing of the manuscript; effective participation in research orientation; critical review of the literature.

Pamella Paola Bezerra de Oliveira: elaboration and writing of the manuscript; critical review of the literature.

Daniela Mayumi Takano: approval of the final version of the manuscript; effective participation in research orientation; critical review of the manuscript.

Idalina Inês Fonseca Nogueira Cambuim: approval of the final version of the manuscript; effective participation in research orientation; critical review of the manuscript.

Conflicts of interest

None declared.

References

1. Queiroz JPAF, Sousa FDN, Lage RA, Izael MA, Santos AG. Criptococose-uma revisão bibliográfica. *Acta Vet Bras.* 2008;2:32–8.
2. Azulay RD, Azulay DR, Abulafia LA. *Dermatologia.* 6th ed. Rio de Janeiro: Guanabara Koogan; 2013.
3. Bivanco FC, Machado CDS, Martins EL. Criptococose cutânea. *Arq Med ABC.* 2006;31:102–9.

4. Pinto Junior VL, Galhardo MCG, Lazéra M, Wanke B, Reis RS, Perez M. Criptococose associada à AIDS. A importância do cultivo da urina no seu diagnóstico. *Rev Soc Bras Med Trop.* 2006;39:230–2.
5. Trope BM, Fernandes ALC, Maceira MHJP, Barreiros MGC. Paniculite criptocócica em transplantado renal. *An Bras Dermatol.* 2008;83:233–6.

Deborah Lucena Markman ^{a,*},
Pamella Paola Bezerra de Oliveira ^a,
Daniela Mayumi Takano ^b,
Idalina Inês Fonseca Nogueira Cambuim ^c

^a Department of Dermatology, Hospital Otávio de Freitas, Recife, PE, Brazil

^b Department of Pathology, Universidade Federal de Pernambuco, Recife, PE, Brazil

^c Mycology Laboratory, Hospital Otávio de Freitas, Recife, PE, Brazil

* Corresponding author.

E-mail: deborahmarkman@gmail.com (D.L. Markman).

Received 27 May 2018; accepted 4 July 2019

Available online 18 March 2020

<https://doi.org/10.1016/j.abd.2019.07.009>

0365-0596/ © 2020 Sociedade Brasileira de Dermatologia.

Published by Elsevier España, S.L.U. This is an open access article under the CC BY license

(<http://creativecommons.org/licenses/by/4.0/>).

Terra firma-forme dermatosis: an underdiagnosed condition ☆☆☆



Dear Editor,

A 12-year-old girl, who had no co-morbidities, sought dermatological care due to the emergence of brownish spots that looked like “dirt”, which were spread through the body and had progressively evolved in the previous two years. This condition caused great social impact to the patient, given that she suffered from discrimination at school. She had used ketoconazole cream as prescribed by a physician of the Basic Health Unit; however, there was no clinical response. The patient noticed that the lesions became discreetly clearer after intense rubbing with gauze, but without improvement after washing with soap and water.

The dermatological examination indicated that the patient had hyperkeratotic brownish plaques with a dotted pattern, affecting the neck, back, abdomen, and, in a less evident manner, the lower limbs (Figs. 1 and 2). After suspecting the presence of terra firma-forme, the lesions were

rubbed with gauze embedded in 70% alcohol and the plaques were removed (Fig. 3).

“Terra firma-forme” is a Latin expression, which means “solid earth”, also known as Duncan’s dirty dermatosis. It is a benign and idiopathic skin disorder that was described in 1987.^{1–3} Its prevalence and incidence are unknown, because it is an underdiagnosed disorder.¹ The cases described in the literature have indicated greater involvement during childhood and adolescence.^{2,3}

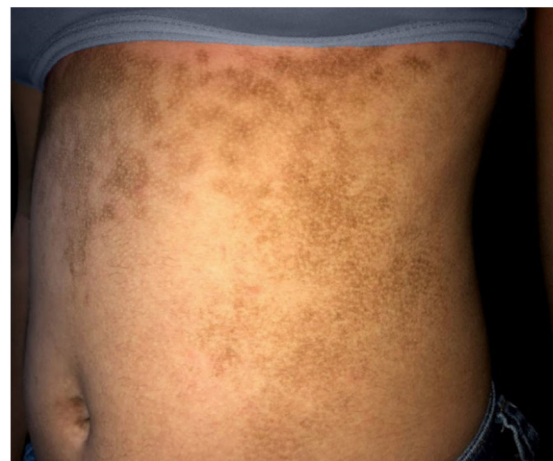

Figure 1 Hyperkeratotic brownish plaques with a dotted pattern affecting the abdomen.

☆ How to cite this article: Badaró BA, Diniz LM, Nogueira PSE. Terra firma-forme dermatosis: an underdiagnosed condition. *An Bras Dermatol.* 2020;95:397–8.

☆☆ Study conducted at the Hospital Universitário Cassiano Antônio Moraes, Vitória, ES, Brazil.