

CASE LETTER

Sporadic form of epidermolysis bullosa simplex with mottled pigmentation ☆☆☆

Dear Editor,

Epidermolysis bullosa (EB) composes a group of hereditary bullous disorders in which the blisters arise spontaneously or are triggered by minimal trauma. Koebner suggested this denomination in 1886. EB is divided into four major types (simplex, junctional, dystrophic, and Kindler syndrome) and several distinct clinical phenotypes, according to the level of skin cleavage, as well as clinical and molecular characteristics.^{1,2}

Epidermolysis bullosa simplex with mottled pigmentation (EBS-MP) is an uncommon subtype of epidermolysis bullosa simplex (EBS; Online Mendelian Inheritance in Man [OMIM] No. 131960). It is characterized by non-cicatricial blisters, mainly at the distal extremities, and progressive mottled hyperpigmentation. Until 2013, only 15 families and eight sporadic cases had been reported, according to the data from the Hospital Infantil Universitário Niño Jesus, in Madrid, which motivated this report.²

The patient was a 2-year-old girl, phototype III, with a history of blistering skin since birth. On dermatological examination she had desiccated blisters on the feet, as well as hyper- and hypochromic macules scattered over the tegument with mottled appearance (Figs. 1 and 2). Normochromic papules on the dorsal region of the fingers and onychodystrophy were also seen. The blisters appeared spontaneously or after minimal trauma, according to the mother's report, and were located mainly at the distal extremities of the limbs. At two months of age, the hyper- and hypochromic macules began. The mother also referred episodes of oral mucositis. Immunomapping result (Fig. 3) coupled with the patient's clinical and laboratory findings confirmed the diagnosis of EBS-MP. This is probably a sporadic case since family history of EB or other bullous disease is negative. The patient is under outpatient clinic follow-up. Family orientations were conducted in order to reduce the occurrence of new blisters and improve the coexistence of the patient with her genodermatosis.

First described in 1979 by Fischer and Gedde-Dahl, EBS-MP begins in childhood and has a genetic origin. It is a basal

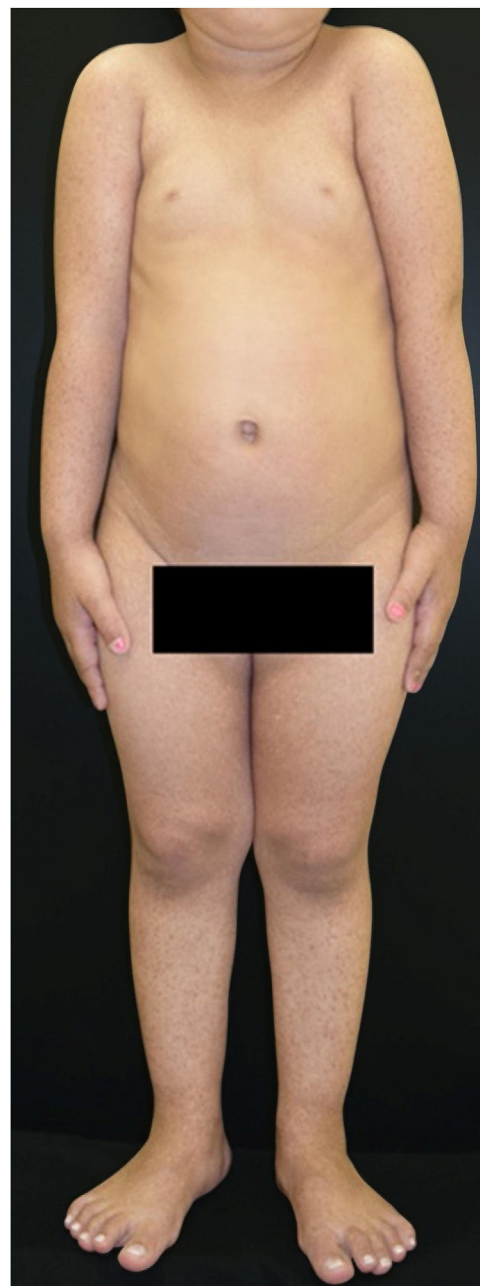

Figure 1 Disseminated hyper- and hypochromic macules scattered over the tegument with mottled appearance.

☆ How to cite this article: Ferreira FR, Pereira CF, Moretto JC, Naville MP. Sporadic form of epidermolysis bullosa simplex with mottled pigmentation. An Bras Dermatol. 95:536-8.

☆☆ Study conducted at the Hospital Universitário de Taubaté, Taubaté, SP, Brazil.

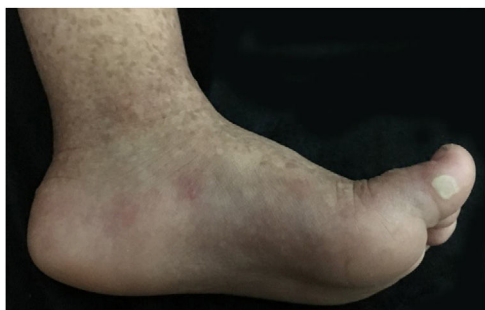

Figure 2 Close-up. Desiccated blisters and vesicles on the left foot.

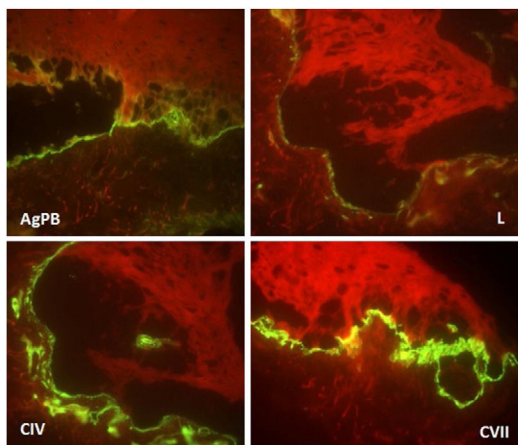


Figure 3 Immunomapping: fluorescence deposition on the blister floor (dermal side) observed with all antigenic markers (bullous pemphigoid antigen, laminin, collagens IV and VII).

EBS caused by a mutation in the *KRT5* gene that encodes cytokeratin 5. It occurs most commonly due to a punctual heterozygous p24L mutation in the non-helical V1 domain of cytokeratin 5.^{1,2}

The diagnosis of this dermatosis is based on typical clinical findings, family history, immunomapping, and/or transmission electron microscopy, as well as molecular/mutation analysis when possible.²

Clinically, it is characterized by non-cicatricial blisters, mainly at the distal extremities, as well as progressive mottled hyperpigmentation, which does not occur at the site of the blisters and often disappears in adulthood. Some cases may be accompanied by hypopigmented macules, as could be seen in this patient. There are also reports of palmar and plantar focal hyperkeratosis. Small acral verrucous papules, onychodystrophy, and mild involvement of the oral mucosa can be observed during childhood. Uncommon findings include photosensitivity and dental disorders (caries).²

The differential diagnosis of EBS-MP includes other types of EBS (mainly the herpetiformis type of Dowling-Meara), Kindler syndrome, Naegeli-Franceschetti-Jadassohn (NFJ) ectodermal dysplasia, other forms of dyschromia, Dowling-Degos disease, and even atypical cases of Darier's disease with mutations in *ATP2A2*.²⁻⁴

Due to the clinical hypothesis of EB and to determine the level of skin cleavage, immunomapping or transmission electron microscopy should be performed. The immunomap-

ping has diagnostic accuracy similar to transmission electron microscopy, with the advantage of simple and fast execution and reading. It is associated with the use of monoclonal antibodies and may be considered an indirect immunofluorescence technique. In the EBS, the skin cleavage occurs in the basal layer (intra-epidermal), and fluorescence deposition on the blister floor (dermal side) is seen with all antigenic markers (bullous pemphigoid antigen, laminin, collagens IV and VII), as observed in this case.⁵

Ultrastructural analysis of the pigmented areas in this form of EBS demonstrates abundant mature melanosomes within the basal cells.²

Thus, this report details a rare case of a possibly sporadic EBS-MP. The authors emphasize the rarity of this subtype of EBS and its remarkable clinical characteristics favoring future diagnoses, and highlight its benign character, with no scarring or deforming lesions and regression of hyperpigmentation in adulthood.

Financial support

None declared.

Authors' contributions

Flávia Regina Ferreira: Approval of final version of the manuscript; conception and planning of the study; drafting and editing of the manuscript; collection, analysis, and interpretation of data; intellectual participation in the propaedeutic and/or therapeutic conduct of the studied cases; critical review of the literature; critical review of the manuscript.

Carolina Fernandes Pereira: Approval of final version of the manuscript; conception and planning of the study; drafting and editing of the manuscript; critical review of the literature.

Juliana Carvalho Moretto: Approval of final version of the manuscript; conception and planning of the study; drafting and editing of the manuscript; critical review of the literature.

Mariana Patriota Naville: Approval of final version of the manuscript; conception and planning of the study; drafting and editing of the manuscript; critical review of the literature.

Conflicts of interest

None declared.

References

1. Fine JD, Bruckner-Tuderman L, Eady RA, Bauer EA, Bauer JW, Has C, et al. Inherited epidermolysis bullosa: updated recommendations on diagnosis and classification. *J Am Acad Dermatol.* 2014;70:1103–26.
2. Echeverría-García B, Vicente A, Hernández Á, Mascaró JM, Colmenero I, Terrón A, et al. Epidermolysis bullosa simplex with mottled pigmentation: a family report and review. *Pediatr Dermatol.* 2013;30:e125–31.
3. Hamada T, Yasumoto S, Karashima T, Ishii N, Shimada H, Kawano Y, et al. Recurrent p.N767S mutation in the *ATP2A2* gene in a

Japanese family with haemorrhagic Darier disease clinically mimicking epidermolysis bullosa simplex with mottled pigmentation. *Br J Dermatol.* 2007;157:605–8.

4. Zhang J, Li M, Yao Z. Updated review of genetic reticulate pigmentary disorders. *Br J Dermatol.* 2017;177:945–59.
5. Alves ACF, Machado MCMR, Cymbalista NC, Oliveira ZNP, Sotto MN, Prianti MG, et al. Immunomapping in the diagnosis of hereditary epidermolysis bullosa dystrophica. *An Bras Dermatol.* 2001;76:551–60.

Flávia Regina Ferreira *, Carolina Fernandes Pereira ,
Juliana Carvalho Moretto , Mariana Patriota Naville 

Dermatology Service, Hospital Universitário de Taubaté, Taubaté, SP, Brazil

* Corresponding author.

E-mail: dermagica@uol.com.br (F.R. Ferreira).

Received 1 May 2019; accepted 20 August 2019

Available online 14 May 2020

<https://doi.org/10.1016/j.abd.2019.08.033>

0365-0596/ © 2020 Sociedade Brasileira de Dermatologia.

Published by Elsevier España, S.L.U. This is an open access article under the CC BY license (<http://creativecommons.org/licenses/by/4.0/>).

Rare presentation of Rothmund-Thomson syndrome with novel compound heterozygous mutations of the RECQL4 gene^{☆☆}



Dear Editor,

Rothmund-Thomson syndrome (RTS) is a rare autosomal recessive disorder that is characterized by facial rash (poikiloderma, a diagnostic hallmark), growth retardation, sparse scalp hair/eyelashes/eyebrows, juvenile cataracts, skeletal abnormalities, radial ray defects, and a predisposition to cancer. There are two clinical forms: type I, which is characterized by poikiloderma, ectodermal dysplasia, and juvenile cataracts with unknown etiology, and type II which is characterized by poikiloderma, congenital bone defects, an increased frequency of malignancy (especially osteosarcoma), and RECQL4 (8q24.3) mutation.¹ To date, around 400 cases have been reported.

Here, the authors report a case of poikiloderma and growth retardation in a Chinese girl presenting two RECQL4 mutations in a novel, compound heterozygous arrangement (c.2492_2493del and c.1391-2A>C) recorded *via* mutational screening, which is the first reported in RTS.

The proband is a 2-year-old girl with poikiloderma bilaterally on her face and ears. Her parents complained that their younger daughter showed erythema, swelling, and blistering bilaterally on her face since the age of 6 months, which gradually developed to reticulated hypo- and hyperpigmentation. The girl also presented with thinning of eyebrows, photosensitivity, and gastrointestinal problems including chronic emesis or diarrhea. Neither her parents nor her 5-year-old sister has similar symptoms. The patient was born at full term with a mild toe abnormality. However, slow weight gain, short stature, and teeth retardation were noted on a physical examination. The dermatological examination found bilateral depigmentation, hyperpigmentation,

punctate atrophy, and telangiectasia over the patient's face and ears (Fig. 1). Bone mineral density measurement was performed at 1 year of age, which showed low bone mineral density. Her cognitive ability, ophthalmic testing, and other examination results were within normal limits and no other alterations were found.

For differential molecular diagnosis of poikiloderma, targeted exome sequencing was performed. Mutational screening for BLM, the defective gene in Bloom's syndrome and other poikiloderma-related diseases, was negative. Gene sequencing revealed two distinct heterozygous mutations on the RECQL4 gene (Fig. 2). One of them is a point mutation located in exon 9, consisting of a change of adenine for cytosine (c.1391-2A>C), which was found in her unaffected father and sister. This mutation has not been reported, but the possible effect on the protein through a splice acceptor variant can be assumed. On the other allele, the mutation is a deletion of two nucleotides found in exon 16 (c.2492_2493delAT), which produces a frame shift (p.His831Argfs); this mutation is known to be rare and last evaluated by Kitao et al.² This mutation was found in her unaffected mother. These two mutations of the proband respectively come from her father and mother, known as compound heterozygous mutations, and accord with the autosomal recessive inheritance law. Her sister only presents c.1391-2A>C, which is a heterozygous mutation and, theoretically, she won't show any symptoms.

The patient reported here has the clinical signs like poikiloderma, sparse eyebrows, small stature, dental abnormality, and mild skeletal abnormality, which are mentioned in the previous articles.^{3,4} No cataracts and cancer have been found so far. Unlike other previous cases, the lesion doesn't affect her extremities, and the authors consider that she is too young to show all the symptoms. RTS was diagnosed according to typical lesion and mutation of RECQL4 gene, and the patient was advised to avoid sun exposure and undergo annual checkups for the eyes, skin, and bones.

The novels compound heterozygous RECQL4 mutations presented in this patient is the first reported in RTS. Loss of RECQL4 protein function occurs in approximately two-thirds of RTS patients and is associated with risk of osteosarcoma.⁵ Further functional studies to confirm the protein-damaging effect are needed to proceed. Poikiloderma is a symptom of many systemic diseases, such as lupus erythematosus, Bloom

[☆] How to cite this article: Zhang X, Geng S, Zheng Y. Rare presentation of Rothmund-Thomson syndrome with novel compound heterozygous mutations of the RECQL4 gene. *An Bras Dermatol.* 2020;95:538-40.

^{☆☆} Study conducted at the Department of Dermatology, Second Affiliated Hospital, Xi'an Jiaotong University, Shaanxi, China.