

Dermscopy of crusted lesion: diagnostic challenge and choice of technique for the analysis☆☆



Dear Editor,

A 52-year-old male patient, phototype IV, with significant photodamage complained of a painful chest lesion, with a progressive increase in the 6 previous months. During the physical examination, he had an erythematous plaque measuring 4 × 8 cm, with yellowish crusts and violaceous borders on the left anterosuperior thorax region (Fig. 1). Dermoscopy was inconclusive due to the presence of non-specific yellowish crusts on the lesion (Fig. 2).

After applying wet compresses with saline solution, the crusts were carefully removed. To avoid contact with the lesion surface, polarized light dermoscopy was performed, which demonstrated the presence of glomerular vessels, suggestive of Bowen's disease (BD) (Fig. 3).¹ In view of this picture, an excisional biopsy was performed. Histopathological examination confirmed the diagnosis of BD.

Dermoscopy is important in the diagnosis of pigmented and non-pigmented lesions.¹ In non-pigmented lesions, the vascular pattern can lead to the diagnosis, but in the reported case, it was not possible to achieve the diagnosis due to the presence of crusts. The presence of yellowish crusts at dermoscopy has been previously described in 78.8% of 146 evaluated BD lesions, but it is not specific, and the presence of crusts alone is not a sufficient criterion for this diagnosis.^{2,3} In crusted lesions, the removal of the crusts may allow the observation of other dermoscopic structures that can help achieve the diagnosis. The removal of crusts should be performed with caution to avoid damage to the epithelium because this maneuver can allow the observation of other dermoscopic structures that make the diagnosis possible.

Financial support

None declared.

Authors' contributions

Agnes Carvalho Andrade: Approval of the final version of the manuscript; study design and planning; drafting and editing of the manuscript; collection, analysis, and interpretation of data; effective participation in the research orientation; critical review of the literature; critical review of the manuscript.

Marina Zoéga Hayashida: Approval of the final version of the manuscript; study design and planning; drafting

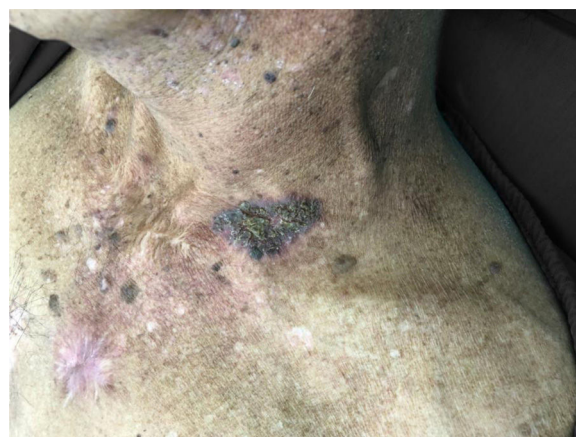

Figure 1 Desquamative plaque on the anterosuperior thorax.

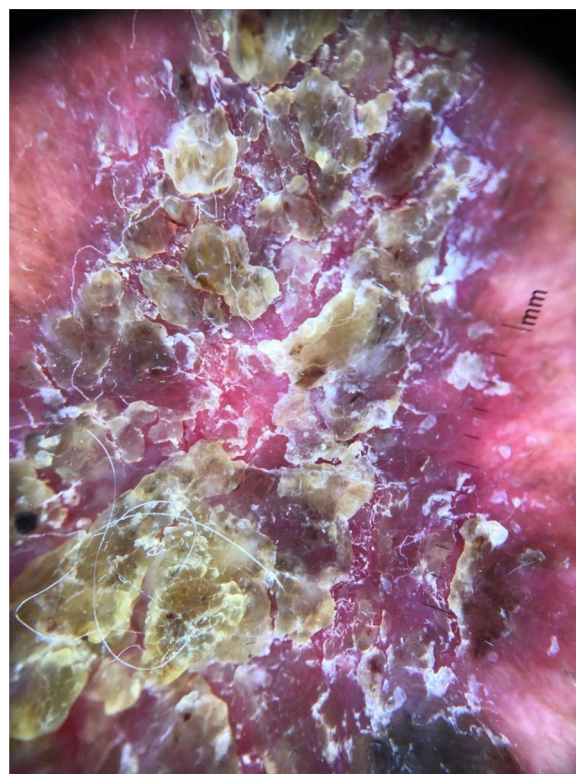


Figure 2 Dermoscopy before removal of crusts.

and editing of the manuscript; effective participation in research orientation.

Milvia Maria Simões e Silva Enokihara: Approval of the final version of the manuscript; drafting and editing of the manuscript; effective participation in the research orientation; critical review of the literature; critical review of the manuscript.

Sérgio Henrique Hirata: Approval of the final version of the manuscript; study design and planning; drafting and editing of the manuscript; collection, analysis, and interpretation of data; effective participation in the research orientation; intellectual participation in the propaedeutic and/or therapeutic conduct of the studied cases; critical review of the literature.

☆ How to cite this article: Andrade AC, Hayashida MZ, Enokihara MMSS, Hirata SH. Dermoscopy of crusted lesion: diagnostic challenge and choice of technique for the analysis. An Bras Dermatol. 2021;96:387-8.

☆☆ Study conducted at the Department of Dermatology, Universidade Federal de São Paulo, São Paulo, SP, Brazil.

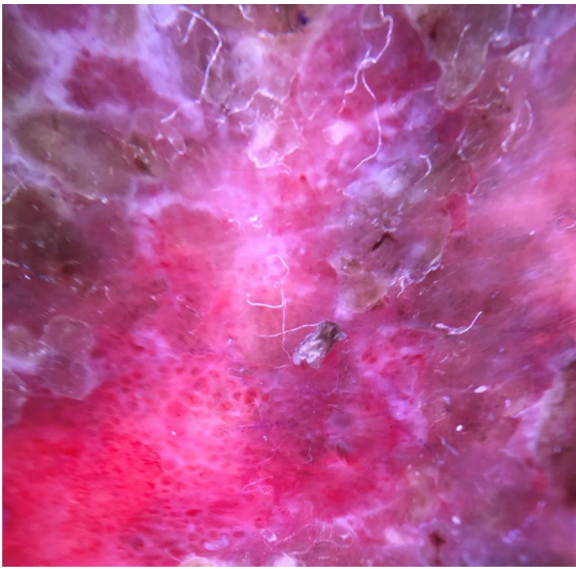






Figure 3 Dermoscopy after removal of crusts, displaying glomerular vessels.

Conflicts of interest

None declared.

References

1. Braun RP, Rabinovitz HS, Oliviero M, Kopf AW, Saurat J-H. Dermoscopy of pigmented skin lesions. *J Am Acad Dermatol.* 2005;52:109–21.
2. Yang Y, Lin J, Fang S, Han S, Song Z. What's new in dermoscopy of Bowen's disease: two new dermoscopic signs and its differential diagnosis. *Int J Dermatol.* 2017;56:1022–5.
3. Shakya NM, LeAnder RW, Hinton KA, Stricklin SM, Rader RK, Hagerty J, et al. Discrimination of squamous cell carcinoma in situ from seborrheic keratosis by color analysis techniques requires information from scale, scale-crust and surrounding areas in dermoscopy images. *Comput Biol Med.* 2012;42:1165–9.

Agnes Carvalho Andrade *, Marina Zoéga Hayashida ,
Milvia Maria Simões e Silva Enokihara ,
Sérgio Henrique Hirata 
Department of Dermatology, Universidade Federal São Paulo, São Paulo, SP, Brazil

*Corresponding author.

E-mail address: dra.agnesandrade@gmail.com (A.C. Andrade).

Received 20 November 2019; accepted 30 June 2020
Available online 15 March 2021

<https://doi.org/10.1016/j.abd.2020.06.016>

0365-0596/ © 2021 Sociedade Brasileira de Dermatologia.

Published by Elsevier España, S.L.U. This is an open access article under the CC BY license (<http://creativecommons.org/licenses/by/4.0/>).

Hydroa vacciniforme-like lymphoproliferative disorder (HV-LPD) is an Epstein-Barr virus (EBV) associated disease^{☆,☆☆}



Dear Editor,

We present a 12-year-old Hispanic male with a 6-year history of "nodules" that ulcerated in the face, lower and upper limbs which left multiple scars. He attended for 20-days of facial edema, associated with a decrease in visual acuity. The ophthalmologist reported necrosis of the left eye. During the physical examination he presented periorbital edema, left frontal vesico-blisters, which left varioliform scars (Fig. 1). A skin biopsy was performed with evidence of epidermal necrosis, atypical perivascular, and perianaxial lymphoid infiltrates with angiocentricity. Immunohistochemistry was compatible with cytotoxic T lymphocytes (CD3⁺ CD8⁺ Perforine⁺ CD56⁻) with a 20% of ki67, and a positive in situ hybridization for Epstein-Barr virus (EBER) test (Figs. 2 and 3). A conjunctiva biopsy was performed, with evidence of necrotic tissue, and a positive polymerase chain reaction for EBV. Viral load for EBV in blood was positive (197,929 copies/mL). With all of the above, a diagnosis of HV-LPD was performed. CT scans report cervical adenopathies and hepatosplenomegaly. Biopsy of cervical node and bone marrow was negative for malignancy. Proper

phocytes (CD3⁺ CD8⁺ Perforine⁺ CD56⁻) with a 20% of ki67, and a positive in situ hybridization for Epstein-Barr virus (EBER) test (Figs. 2 and 3). A conjunctiva biopsy was performed, with evidence of necrotic tissue, and a positive polymerase chain reaction for EBV. Viral load for EBV in blood was positive (197,929 copies/mL). With all of the above, a diagnosis of HV-LPD was performed. CT scans report cervical adenopathies and hepatosplenomegaly. Biopsy of cervical node and bone marrow was negative for malignancy. Proper

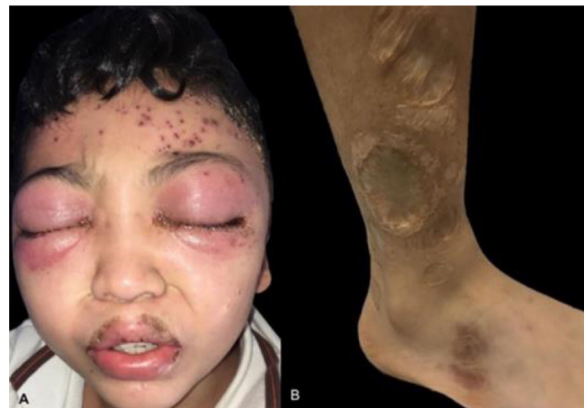

Figure 1 (A), Periorbital edema, and erythema with left frontal vesico-blisters with hemorrhagic content. (B), Multiple atrophic and some anetodermic scars on the lower limbs.

[☆] How to cite this article: Ordoñez-Parra J, Mejía Cortes M, Tamayo-Buendía MM, Infante Gómez AM. Hydroa vacciniforme-like lymphoproliferative disorder (HV-LPD) is an Epstein-Barr virus (EBV) associated disease. *An Bras Dermatol.* 2021;96:388–90.

^{☆☆} Study conducted at the Hospital Universitario San Ignacio, Bogotá, Colombia.