

8. Espósito ACC, Brianezi G, de Souza NP, Miot LDB, Marques MEA, Miot HA. Exploring pathways for sustained melanogenesis in facial melasma: an immunofluorescence study. *Int J Cosmet Sci*. 2018;40:420–4.

* Corresponding author.

E-mail address: anaclaudiaesposito@gmail.com (A.C. Espósito).

Received 10 April 2020; accepted 15 May 2020
Available online 15 March 2021

Ana Cláudia Cavalcante Espósito *,
Nathália Pereira de Souza ,
Luciane Donida Bartoli Miot , Hélio Amante Miot ,
Departments of Dermatology and Pathology, Faculty of
Medicine, Universidade Estadual Paulista, Botucatu, SP,
Brazil

<https://doi.org/10.1016/j.abd.2020.05.016>

0365-0596/ © 2021 Sociedade Brasileira de Dermatologia.

Published by Elsevier España, S.L.U. This is an open access article under the CC BY license (<http://creativecommons.org/licenses/by/4.0/>).

Profile of pediatric patients with myiasis treated at a tertiary hospital in Rio de Janeiro^{☆,☆☆}



Dear Editor,

Myiasis is a dermatozoonosis, defined by the infestation of living animal tissues (mammals, birds, reptiles, and amphibians) by fly larvae, which can deposit their eggs in the natural orifices of their hosts, in skin continuity solutions or healthy skin, in furuncular myiasis. The larvae grow and feed on the host's tissue, causing severe pain and tissue destruction. This is a neglected disease, resulting from low socioeconomic conditions and the delay in seeking assistance.^{1,2} Surveys on the epidemiological profile of pediatric patients with myiasis are scarce in the literature.

This is an observational study carried out at Hospital Federal do Andaraí (HFA), in the city of Rio de Janeiro, State of Rio de Janeiro, Brazil, where patients aged up to 12 years with myiasis were selected and treated from 2007 to 2015. Socioeconomic and clinical data were collected from the patients' medical record, the larvae were extracted and identified according to taxonomic keys, in the Diptera Study Laboratory of the Federal University of the State of Rio de Janeiro – UNIRIO, as well as the adult insects preserved for around 10 days in sterile material.^{3,4} The study was approved by the UNIRIO Ethics Committee and the HFA Study Center.

A total of 69 patients were evaluated, aged less than or up to 12 years, in the studied period, representing about 19% of the 368 cases treated in all age groups. Most patients were females, 58 (84%), and 47 (68%) were dark-skinned. The family income was mostly up to 2 minimum wages and no head of the family had finished higher education. Only 48 (70%) had access to running water at home, 37 (54%) had access to regular garbage collection services and 41 (62%) had sanitary sewage collection system at the household, of which 18 (44%) had no access to a public sewage system and

disposed of the sewage into a nearby pit. Seven (10%) were in a situation of vulnerability (Table 1 and Fig. 1) and only 21 (30%) of the treated children were enrolled in school or day-care centers during the treatment period. The distribution by age group was balanced, with a mean age of 5.89 ± 3.38 years, with a lower prevalence in children under 1 year.

The cases originated mainly in the North region of the city of Rio de Janeiro, with 42 (61%) of the cases, with emphasis on the regions of great Tijuca and great Méier, which accounted for 22 (52%) of all cases in the North region of the city, the geographical area where the Andaraí Federal Hospital is located. In this same region, 4 (6%) lived in shelters or orphanages and 3 (4%) were homeless in neighborhoods adjacent to the hospital; one of these patient's entire family had lived for years in an abandoned milk factory. Two (3%) lived in the downtown region and 18 (26%) lived in Baixada Fluminense.

The scalp was the preferred site in 63 (91%) of the children. Among the predisposing factors and associated diseases, other dermatozoonoses represented by pediculosis and scabies, allergic dermatitis, and pyoderma were observed as the most prevalent ones (Table 1). The maximum number of larvae removed from a patient was 36 and the minimum was only one, with an average of 11.5 larvae per patient.

Cavitary or necrobiontophagous myiasis, those associated with pre-existing wounds and low socioeconomic status and poor hygiene conditions, were observed in 58 patients (91%), with *Cochliomyia hominivorax* being the most prevalent species, present in 56 (87%) patients, *Cochliomyia macel-*

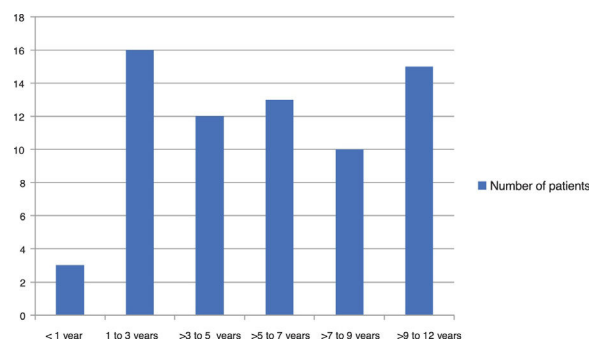


Figure 1 Distribution of myiasis cases in the pediatric population by age group, treated at Hospital Federal do Andaraí between 2007 and 2015.

[☆] How to cite this article: Rodrigues FT, D'Acari AM, Lessa CSS, Aguiar VM. Profile of pediatric patients with myiasis treated at a tertiary hospital in Rio de Janeiro. *An Bras Dermatol*. 2021;69:369–72.

^{☆☆} Study conducted at the Hospital Federal do Andaraí and Laboratório de Estudo de Dípteros da Universidade Federal do Estado do Rio de Janeiro, Rio de Janeiro, RJ, Brazil.

Table 1 Socioeconomic and clinical characteristics of pediatric patients with myiasis treated at the Andaraí Federal Hospital between 2007 and 2015.

| Characteristics | n | % |
|--|----|----|
| Socioeconomic | | |
| Self-declared skin color | | |
| White | 8 | 12 |
| Black | 30 | 43 |
| Brown | 17 | 25 |
| Unknown | 14 | 20 |
| Average monthly family income (minimum-wages between R\$380 and R\$788; 2007–2015) | | |
| None | 7 | 10 |
| Up to 2 minimum wages | 37 | 54 |
| Between 2 and 4 minimum wages | 11 | 16 |
| More than six minimum wages | 1 | 1 |
| Unknown | 13 | 19 |
| Maternal level of schooling | | |
| Illiterate | 15 | 22 |
| Incomplete Elementary School | 23 | 33 |
| Complete Elementary School | 10 | 15 |
| Incomplete High School | 3 | 4 |
| Complete High School | 6 | 9 |
| Incomplete Higher Education | 1 | 1 |
| Unknown | 11 | 16 |
| Regular garbage collection service or appropriate disposal pit close to home | | |
| Yes | 37 | 54 |
| No | 27 | 39 |
| Unknown | 5 | 7 |
| Running water at the household | | |
| Yes | 48 | 70 |
| No | 16 | 23 |
| Unknown | 5 | 7 |
| Sewage collection system at the household | | |
| Yes | 41 | 62 |
| No | 22 | 35 |
| Unknown | 6 | 3 |
| House occupancy status | | |
| Owned | 44 | 64 |
| Rented | 17 | 25 |
| Homeless person | 3 | 4 |
| Living in a shelter | 4 | 6 |
| Unknown | 1 | 1 |
| Clinical information | | |
| Predisposing factors and associated comorbidities | | |
| Bacterial infection (impetigo, cellulitis) | 19 | 27 |
| Trauma | 7 | 10 |
| Pediculosis | 26 | 38 |
| Scabies | 4 | 6 |
| Chemical dermatitis | 4 | 6 |
| Allergic dermatitis (including scrofulous prurigo) | 25 | 36 |
| Seborrheic dermatitis | 5 | 7 |
| Atopic dermatitis | 4 | 6 |
| Affected body sites | | |
| Parietal scalp | 32 | 46 |
| Temporal scalp | 8 | 12 |
| Frontal scalp | 4 | 6 |
| Occipital scalp | 19 | 28 |
| Umbilical scar | 1 | 1 |
| Auricle | 1 | 1 |
| Lower limb | 2 | 3 |

Table 1 (Continued)

| Characteristics | n | % |
|-------------------|-----|----|
| Number of lesions | | |
| Average | 1.8 | – |
| One | 42 | 61 |
| Two | 8 | 12 |
| Three | 14 | 20 |
| Five or more | 5 | 7 |

laria larvae were found in three patients (5%), *Chrysomya putoria* in one (1%), *Chrysomya albiceps* in one (1%) and *Musca domestica* in one patient (1%). There were three cases of co-infection by two of these species.

Six (9%) cases of furuncular myiasis were caused by the species *Dermatobia hominis*, a primary disease of cattle and horses that can occur in the general population exposed to the risk in rural and even in urban areas, which does not fit the poverty profile.^{1,2,5,6} There was one case of concomitant infestation of father and daughter, raising the possibility of family co-infection. In some cases, the myiasis occurred under pre-existing conditions: four cases of contact dermatitis due to primary irritant resulting from the use of guanidine, a substance used for hair straightening.

Moreover, there was an association with a thermal burn wound (one case), cutaneous varicella lesion (one case), as well as a tinea capitis lesion (one case).

Although manual extraction is the treatment of choice, ivermectin is widely used in extensive lesions, when it is not possible to remove all larvae, but it should be avoided in children under 5 years of age, according to the medication package insert. Sixteen (23%) of the cases required hospitalization, mainly due to the social vulnerability that made home treatment unfeasible.

A total of 61 patients (88%) received antibiotic therapy with Cephalexin or Amoxicillin to prevent and/or treat secondary bacterial infections. Regarding the prevalence of myiasis cases in the pediatric population, compared to the involvement in all age groups, the present study showed a lower percentage than that found in the literature.^{7,8}

The main associated factors for larva infestation in children and adolescents are the presence of other infectious and allergic diseases, with emphasis on pediculosis and lesions caused by scrofulous prurigo, with the act of scratching being the main mechanism for the formation of wounds unlike the adult population, in which wound formation is associated with chronic diseases or diabetic foot ulcers, vascular ulcers, in addition to neoplastic wounds, and where carcinomas are the main foci of infestation.

What is also noteworthy is the change in the main infection site, which in pediatric patients is preferentially the cephalic segment, facilitated by pediculosis, traumas and because it is a region not covered by clothing; on the other hand, in adults, the preferred place is the distal third of the lower limbs.^{7–9}

This is a problem, except for cases of furuncular myiasis, which mostly affects populations with greater social vulnerability and with poor hygiene conditions and can be prevented with the advance of basic sanitation coverage and public awareness.

Financial support

Financial support provided by CNPq - Conselho Nacional de Desenvolvimento Científico e Tecnológico.

Authors' contributions

Felipe Tavares Rodrigues: Study design, data collection and analysis, and review of the manuscript.

Antonio Macedo D'Acari: Critical review of the manuscript.

Claudia Soares Santos Lessa: Data analysis and critical review.





Valéria Magalhães Aguiar: Data analysis and critical review.

Conflicts of interest

None declared.

References

- Francesconi F, Lupi O. Myiasis. *Clin Microbiol Rev.* 2012;25:79–105.
- Hall MJ, Wall RL, Stevens JR. Traumatic myiasis: a neglected disease in a changing world. *Annu Rev Entomol.* 2016;61:159–76.
- Serra-Freire NM, Mello RP. Entomologia e acarologia na medicina veterinária. Rio de Janeiro: LF Livros de Veterinária; 2006.
- Mello RP. Chave para identificação das formas adultas das espécies da família Calliphoridae (Diptera, Brachycera, Cyclorrhapha) encontradas no Brasil. *Entomol Vect.* 2003;10:255–68.
- Rodrigues FT, D'Acari AM, Aguiar VM, Lessa CSS. Miasis furuncular como posible diagnóstico diferencial en viajeros y visitantes de la selva en Brasil: un informe de tres casos. *Dermatol Peru.* 2019;29:199–201.
- Marquez AT, Mattos MS, Nascimento SB. Myiasis associated with some socioeconomic factors in five urban areas of the State of Rio de Janeiro. *Rev Soc Bras Med Trop.* 2007;40:175–80.
- Ferraz ACP, De Almeida VRG, Jesus DM, Rotatori GN, Nunes R, Proença B, et al. Epidemiological study of myiasis in the Hospital do Andaraí, Rio de Janeiro, including reference to an exotic etiological agent. *Neotrop Entomol.* 2011;40:393–7.
- Rodrigues FT, Aguiar VM, Lessa CS. Diabetic foot ulcers with myiasis: a potential route for resistance gene dissemination for enterococci? *Rev Soc Bras Med Trop.* 2018;51:879.
- Rodrigues FT, Cardozo MRP, Klemig LR, Aguiar VM, Lessa CSS. Carcinomas escamosos com miase, uma nova tendência? *Medicina (Ribeirao Preto Online).* 2018;51:207–10.

Felipe Tavares Rodrigues  a,*
 Antonio Macedo D'Acri  b,
 Claudia Soares Santos Lessa  c,
 Valéria Magalhães Aguiar  c

^a Universidade Federal do Estado do Rio de Janeiro, Rio de Janeiro, RJ, Brazil

^b Service of Dermatology, Hospital Universitário Gaffrée e Guinle, Escola de Medicina e Cirurgia, Universidade Federal do Estado do Rio de Janeiro, Rio de Janeiro, RJ, Brazil

^c Department of Microbiology and Parasitology, Instituto Biomédico, Universidade Federal do Estado do Rio de Janeiro, Rio de Janeiro, RJ, Brazil

* Corresponding author.

E-mail address: medftr@yahoo.com.br (F.T. Rodrigues).

Received 20 April 2020; accepted 30 May 2020

Available online 20 March 2021

<https://doi.org/10.1016/j.abd.2020.05.018>

0365-0596/ © 2021 Sociedade Brasileira de Dermatologia.

Published by Elsevier España, S.L.U. This is an open access article under the CC BY license (<http://creativecommons.org/licenses/by/4.0/>).

Randomized controlled study comparing the use of diphencyprone and anthralin in the treatment of extensive chronic alopecia areata ^{☆,☆☆}



Dear Editor,

Alopecia Areata (AA) does not have a well-established etiopathogenesis and its treatment, especially in the chronic form, remains a challenge.¹

Its clinical spectrum varies from a single plaque to total alopecia (total AA [TAA]) or universal alopecia (UAA) when it affects all body hair. The percentage of hair loss is one of the unquestionable prognostic factors and can be measured using the SALT (Severity of Alopecia Tool) score.^{2,3} UAA and TAA are the types that are most refractory to treatment, and their spontaneous hair regrowth rate is less than 10%.⁴

Diphencyprone (DPCP) is one of the most studied treatments for extensive AA, applied weekly, usually by the doctor.⁵ Anthralin is an old drug, which is used at home and has a lower cost, with few studies carried out on its use in AA.⁶⁻¹⁰ Both medications act by inducing eczema over the alopecic area, with DPCP causing allergic contact dermatitis (CD) and anthralin, irritative CD.

Therefore, it can be assumed that the results of the two drugs are similar; however, there are no studies comparing the effectiveness of anthralin and DPCP in the treatment of AA.

The aim of this study was to compare the efficacy, tolerability, and safety of the two drugs in the treatment of chronic extensive AA (more than one year of duration).

A randomized, controlled clinical trial was performed at the Dermatology Trichology Outpatient Clinic at the Hospital do Servidor Público Municipal de São Paulo - Brazil. After approval by the Ethics Committee (CAAE n°

60888516.1.0000.5442) and signature of the informed consent form, 24 patients who had AA for more than one year, SALT score ≥ 50 , and more than 30 days without treatment, were included and randomly allocated for receiving DPCP (n = 13) (with gradual dose increase until mild eczema was attained) or 2% anthralin in petroleum jelly for 30 min (n = 11). There was an intra-patient control through the initial application only in the right hemicranium. The percentage of hair regrowth was calculated through photos, by a single examiner who was blinded to the treatment group. Because of the characteristics of the medications, it was not possible for the professional applying the medication or the patient to be blinded to the substance used.

The evaluations were carried out at three months, or when there was initial hair regrowth, then at six months. The proposed treatment time was 24 weeks.

The study was funded by the Dermatology Support Fund of the Brazilian Society of Dermatology (FUNADERM).

Out of the 24 patients included, three had total AA (12.5%), 13 UAA (54.2%) and eight had extensive multifocal AA (33.3%). Clinical, demographic, and hair regrowth data are shown in [Table 1](#).

To compare the means, Student's *t* test was used for independent samples; the non-parametric Wilcoxon and Mann-Whitney test was used to compare the medians. To compare proportions, Fisher's exact test was performed. All analyses were performed considering Intention-to-Treat (ITT) and per protocol. The level of significance was set at 5% ($p < 0.05$; two-tailed test).

As for hair regrowth, the improvement was small and similar in the DPCP and anthralin groups ([Figs. 1 and 2](#)). The group treated with DPCP showed some hair regrowth in 38.5% of the cases (5/13) and the anthralin group in 18.2% (2/11), a difference without statistical significance ($p > 0.05$). No patient had more than 75% of hair regrowth in this study. The side effects were similar in both groups ($p = 0.121$ for 3 months and $p = 0.617$ for 6 months).

A recent review found 31 studies using DPCP to treat AA, with 1,638 treated patients, but none of them were randomized or placebo-controlled studies. There was no hair regrowth in 30.7% (22.9%–39.6%) for patients with TAA and UAA, similar to that found in our group.⁵ In this review, the incidence of severe eczema was 30.8%, followed by lymphadenomegaly (25.8%), generalized eczema (15.8%), hyperchromia (12.7%), and influenza-like symptoms (11.1%).⁵

[☆] How to cite this article: Rocha VB, Kakizaki P, Donati A, Machado CJ, Pires MC, Contin LA. Randomized controlled study comparing the use of diphencyprone and anthralin in the treatment of extensive chronic alopecia areata. *An Bras Dermatol*. 2021;96:372–6.

^{☆☆} Study conducted at the Hospital do Servidor Municipal de São Paulo, São Paulo, SP, Brazil.