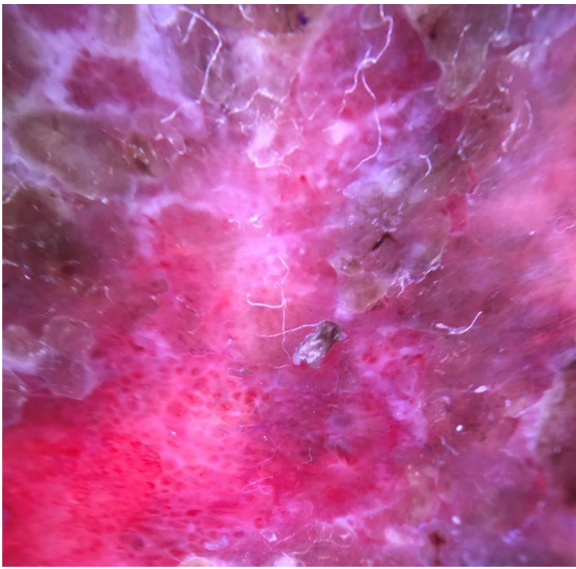





**Figure 3** Dermoscopy after removal of crusts, displaying glomerular vessels.

### Conflicts of interest

None declared.

### References

1. Braun RP, Rabinovitz HS, Oliviero M, Kopf AW, Saurat J-H. Dermoscopy of pigmented skin lesions. *J Am Acad Dermatol.* 2005;52:109–21.
2. Yang Y, Lin J, Fang S, Han S, Song Z. What's new in dermoscopy of Bowen's disease: two new dermoscopic signs and its differential diagnosis. *Int J Dermatol.* 2017;56:1022–5.
3. Shakya NM, LeAnder RW, Hinton KA, Stricklin SM, Rader RK, Hagerty J, et al. Discrimination of squamous cell carcinoma in situ from seborrheic keratosis by color analysis techniques requires information from scale, scale-crust and surrounding areas in dermoscopy images. *Comput Biol Med.* 2012;42:1165–9.

Agnes Carvalho Andrade \*, Marina Zoéga Hayashida ,  
Milvia Maria Simões e Silva Enokihara ,  
Sérgio Henrique Hirata   
Department of Dermatology, Universidade Federal São Paulo, São Paulo, SP, Brazil

\*Corresponding author.

E-mail address: [dra.agnesandrade@gmail.com](mailto:dra.agnesandrade@gmail.com) (A.C. Andrade).

Received 20 November 2019; accepted 30 June 2020  
Available online 15 March 2021

<https://doi.org/10.1016/j.abd.2020.06.016>

0365-0596/ © 2021 Sociedade Brasileira de Dermatologia.

Published by Elsevier España, S.L.U. This is an open access article under the CC BY license (<http://creativecommons.org/licenses/by/4.0/>).

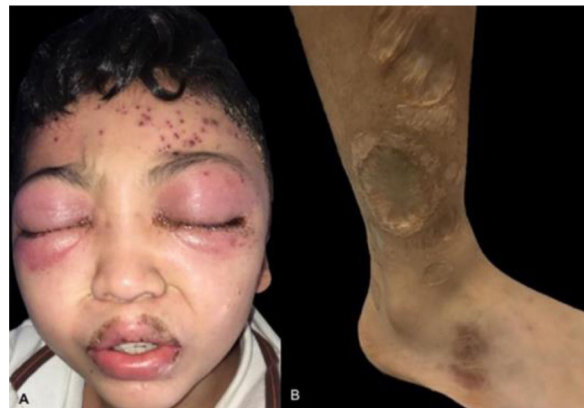## Hydroa vacciniforme-like lymphoproliferative disorder (HV-LPD) is an Epstein-Barr virus (EBV) associated disease<sup>☆,☆☆</sup>



Dear Editor,

We present a 12-year-old Hispanic male with a 6-year history of "nodules" that ulcerated in the face, lower and upper limbs which left multiple scars. He attended for 20-days of facial edema, associated with a decrease in visual acuity. The ophthalmologist reported necrosis of the left eye. During the physical examination he presented periorbital edema, left frontal vesico-blisters, which left varioliform scars (Fig. 1). A skin biopsy was performed with evidence of epidermal necrosis, atypical perivascular, and perianaxial lymphoid infiltrates with angiocentricity. Immunohistochemistry was compatible with cytotoxic T lymphocytes (CD3<sup>+</sup> CD8<sup>+</sup> Perforine<sup>+</sup> CD56<sup>-</sup>) with a 20% of ki67, and a positive in situ hybridization for Epstein-Barr virus (EBER) test (Figs. 2 and 3). A conjunctiva biopsy was performed, with evidence of necrotic tissue, and a positive polymerase chain reaction for EBV. Viral load for EBV in blood was positive (197,929 copies/mL). With all of the above, a diagnosis of HV-LPD was performed. CT scans report cervical adenopathies and hepatosplenomegaly. Biopsy of cervical node and bone marrow was negative for malignancy. Proper

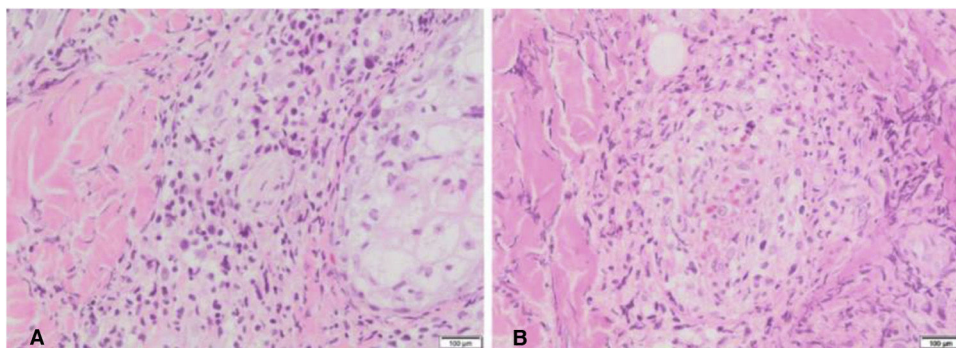
phocytes (CD3<sup>+</sup> CD8<sup>+</sup> Perforine<sup>+</sup> CD56<sup>-</sup>) with a 20% of ki67, and a positive in situ hybridization for Epstein-Barr virus (EBER) test (Figs. 2 and 3). A conjunctiva biopsy was performed, with evidence of necrotic tissue, and a positive polymerase chain reaction for EBV. Viral load for EBV in blood was positive (197,929 copies/mL). With all of the above, a diagnosis of HV-LPD was performed. CT scans report cervical adenopathies and hepatosplenomegaly. Biopsy of cervical node and bone marrow was negative for malignancy. Proper



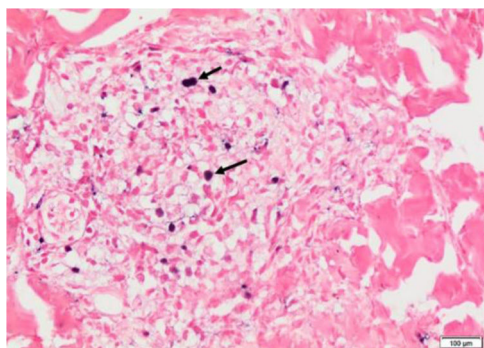
**Figure 1** (A), Periorbital edema, and erythema with left frontal vesico-blisters with hemorrhagic content. (B), Multiple atrophic and some anetodermic scars on the lower limbs.

<sup>☆</sup> How to cite this article: Ordoñez-Parra J, Mejía Cortes M, Tamayo-Buendía MM, Infante Gómez AM. Hydroa vacciniforme-like lymphoproliferative disorder (HV-LPD) is an Epstein-Barr virus (EBV) associated disease. *An Bras Dermatol.* 2021;96:388–90.

<sup>☆☆</sup> Study conducted at the Hospital Universitario San Ignacio, Bogotá, Colombia.



**Figure 2** (A), Atypical perivascular and perianexial lymphoid infiltrates. (B), Angiocentricity.



**Figure 3** Positive in-situ hybridization for EBV (black arrows) (Hematoxylin & eosin, ×100).

treatment with oral thalidomide 100 mg QD was initiated, achieving clinical response.

American cases of HV-LPD have been described in children of Mexico, Peru, and Bolivia.<sup>1,2</sup> According to some studies viral DNA is elevated in most patients, suggesting a chronic EBV infection and a genetic susceptibility for defective EBV-specific immunity.<sup>3,4</sup> Clinically, they present as papulovesicular eruptions, with necrotic centers, in sun-exposed and non-exposed areas.<sup>1</sup> Lie et al. report 12% of patients with ocular symptoms, including corneal nebula, conjunctival swelling, photophobia, and tearing.<sup>5</sup> Unfortunately, our patient had severe ocular involvement which, in the best of our knowledge, there are no previous reports on such association. Therefore, we propose this new feature, due to the clinical picture and positivity for EBV DNA.

Histologically, the epidermis displays extensive ulceration with necrosis and angiocentricity as a common finding in the vessels.<sup>1</sup> Frequent findings include a dense infiltrate of small-to middle size atypical lymphoid cell, pleomorphic nuclei, mainly located around adnexae and blood vessels.<sup>1,4</sup>

Immunohistochemistry reported a lymphoid population (CD3<sup>+</sup>, CD5<sup>+</sup>, and CD7<sup>+</sup>)<sup>1</sup> with cytotoxic or natural killer phenotype (CD8<sup>+</sup> and CD56<sup>+</sup> respectively).<sup>1</sup> The most frequent phenotype is a cytotoxic lymphoid infiltrate, like in our patient, with positive cytotoxic markers.<sup>1-3</sup> Performance of EBER's is encoded for the detection of EBV RNA, positivity of this test have been report up to 100%.<sup>1,3,5</sup>

The main differential diagnoses are classic hydroa vacciniforme. As HV-LPD, classic hydroa vacciniforme appears

in children, has a papulovesicular eruption with a crusted center, and posterior varioliforme scarring. Nonetheless, its localization is limited to sun-exposed areas, with no facial edema nor systemic compromise. Histologic differential diagnosis includes other lymphomas associated with EBV. For example, nasal NK lymphoma is characterized by a rapidly progressive clinical course, positive CD56 and negative CD8 on the immunohistochemistry.

There are no treatment guidelines due to the rarity of the disease. Beltran et al. consider thalidomide as a useful treatment, due to its anti-inflammatory and antiproliferative properties.<sup>2</sup> Four Peruvian patients received thalidomide 100mg orally daily with different results.<sup>2</sup> We report a 12-month clinical remission in our patient, following thalidomide treatment, supporting the use of it as a first-line immunomodulating agent.

### Financial support

None declared.

### Authors' contributions

Juliana Ordoñez-Parra: Patient assessment; literature review; manuscript creation.

Maddy Mejía Cortes: Patient assessment; literature review; manuscript creation.

Margarita Tamayo-Buendía: Patient assessment; literature review; manuscript creation.

Ana María Infante Gómez: Patient assessment and literature review.

### Conflicts of interest

None declared.

### References

1. Magaña M, Massone C, Magaña P, Cerroni L. Clinicopathologic Features of Hydroa Vacciniforme – Like Lymphoma: A Series of 9 Patients. *Am J Dermatopathol.* 2016;38:20–5.

- Beltran BE, Maza I, Moisés-Alfaro CB, Vasquez L, Quiñones P, Morales D, et al. Thalidomide for the treatment of Hydroa Vacciniforme – like lymphoma: Report of four pediatric cases from Peru. *Am J Hematol.* 2014;89:1153–4.
- Liu, Ma C, Wang G, Wang L. Hydroa Vacciniforme – like lymphoproliferative disorder: Clinicopathologic study of 41 cases. *J Am Acad Dermatol.* 2019;81:534–40.
- Lee HY, Baek JO, Lee JR, Park SH, Jeon IS, Roh JY. Atypical Hydroa Vacciniforme – like Epstein-Barr virus associated T/NK-cell lymphoproliferative disorder. *Am J Dermatopathol.* 2012;34:e119–24.
- Lie JT, Groeneveld-van Beek EA, Ham L, Van Der Wees J, Melles GRJ. More efficient use of donor corneal tissue with Descemet Membrane Endothelial Keratoplasty (DMEK): Two lamellar keratoplasty procedures with one donor cornea. *Br J Ophthalmol.* 2010;94:1265–6.

Juliana Ordoñez-Parra \*, Maddy Mejía Cortes ,  
 Maria Margarita Tamayo-Buendía ,  
 Ana María Infante Gómez   
 Hospital Universitario San Ignacio, Bogotá, Colombia

\*Corresponding author.

E-mail address: [juliana.ordonez19@gmail.com](mailto:juliana.ordonez19@gmail.com) (J. Ordoñez-Parra).

Received 29 April 2020; accepted 21 June 2020

Available online 24 March 2021

<https://doi.org/10.1016/j.abd.2020.06.023>

0365-0596/ © 2021 Sociedade Brasileira de Dermatologia.

Published by Elsevier España, S.L.U. This is an open access article under the CC BY license (<http://creativecommons.org/licenses/by/4.0/>).

## N-acetylcysteine for managing neurotic excoriation: encouraging results in two patients<sup>☆,☆☆</sup>



Dear Editor,

Neurotic Excoriation (NE) is characterized by recurrent picking of skin, leading to cutaneous lesions ranging from superficial erosions to deep ulcerations.<sup>1</sup> Acne excoriée (AE) is a subset of NE in which the focus is on acne lesions. NE causes significant psychosocial impairment, which therefore necessitates an effective treatment.<sup>1,2</sup> Although several approaches exist, including behavioral and pharmacological therapies, managing NE is still challenging.<sup>1–3</sup> Glutamatergic dysfunction and oxidative stress are thought to contribute to the pathophysiology of NE.<sup>2,3</sup> Recently, N-Acetylcysteine (NAC), a glutamate modulator and an antioxidant, has been proposed as a promising treatment alternative for NE, and a limited number of reports have shown encouraging results.<sup>1–5</sup>

A 75-year-old woman presented with a 5-year history of itching and scattered wounds on her legs. She had been feeling an irresistible urge to pick her skin, which then became a daily routine that ensued self-inflicted lesions on otherwise normal-appearing skin. Dermatologic examination revealed multiple irregularly shaped erythematous or hyperpigmented, eroded, excoriated, or lichenified papules and nodules of varying size on both legs (Fig. 1A). Complete blood cell count and liver, renal and thyroid function test results were within normal limits. The second case was a 36-year-old woman who presented with a 3-month history of itchy acne-like lesions on her face. She had used many dermocosmetic products without success. She had been habitually picking, scratching, and squeezing these

lesions, and despite these repeated efforts, she was unable to resist this behavior. Dermatologic examination revealed a few comedones, erythematous and excoriated papules, as well as hyperpigmented macules on the forehead (Fig. 2A).

Tzanck smears taken from the lesions stained with May-Grünwald-Giemsa showed no pathology. Upon the diagnosis of NE and AE, respectively, both patients were started on NAC (1200 mg/d, p.o.). The clinical findings subsided after 2- and 6-weeks, in the first (Fig. 1B) and second (Fig. 2B) patient, respectively. No side effects were observed and both patients no longer displayed self-excoriation behavior. The treatment lasted 3-months and 6-weeks, and after cessation of therapy no relapse was observed in 6- and 3-months follow-up in the NE and AE patient, respectively.

There are only a few case reports and two studies in the literature that indicate the potential benefit of NAC for treating NE.<sup>1–5</sup> In those reports, NAC dosage and treatment duration varied greatly (450–3000 mg/d and 1–10 months).<sup>2,3</sup> Side effects including gastrointestinal upset, dry mouth, and dizziness were rarely observed and did not require cessation of therapy.<sup>2–5</sup> Nevertheless, the follow-up data regarding the relapse risk after discontinuation of NAC are unknown.

NE is a psychocutaneous disorder, and given that those patients usually present to dermatology clinics, not only the psychiatrists but also the dermatologists should be aware of new treatment options. Our experience in the present two cases supports the notion that NAC could be a safe and effective alternative for managing NE. However, the appropriate NAC dose and treatment duration for NE, as well as the relapse risk of skin picking behavior after the cessation of therapy, still require clarification in future studies.

### Financial support

None declared.

### Authors' contributions

Deren Özcan: The conception and design of the study; acquisition of data; analysis and interpretation of data; drafting

<sup>☆</sup> How to cite this article: Özcan D. N-acetylcysteine for managing neurotic excoriation: encouraging results in two patients. *An Bras Dermatol.* 2021;96:390–1.

<sup>☆☆</sup> Study conducted at the Department of Dermatology, Faculty of Medicine, Başkent University, Ankara, Turkey.