



CASE LETTER

Clinicodermoscopic and immunohistochemical observation of hepatitis B virus-associated acquired bilateral telangiectatic macules in a Chinese man ☆☆☆



Dear Editor,

Acquired Bilateral Telangiectatic Macules (ABTM) was first reported as telangiectatic pigmented macules primarily on the upper arms in Korean patients with underlying Chronic Liver Disorder (CLD).^{1–3} To date 65 Korean cases and one Chinese case have been reported.^{1–4} Dermoscopy was useful to improve its clinical diagnosis.¹ We describe the clinicodermoscopic and immunohistochemical features of hepatitis B virus-associated ABTM in another Chinese patient.

A 48-year-old Chinese man presented with asymptomatic telangiectatic macules that commenced on the left arm 2.5 years ago and gradually extended to upper limbs and torso. He had a 30-year history of hepatitis B with mildly abnormal liver enzymes during the last three years. Liver enzymes reduced but telangiectasis remained unchangeable after a 1-month course of oral compound glycyrrhizin and glucuro-lactone. No further treatments were given thereafter. There was no history of smoking, drinking, diabetes, hypertension, and ataxia. On examination, multiple, irregular, dark red telangiectatic macules with negative Darier's sign were mainly distributed on the chest and upper limbs (Fig. 1a) and less on the face and upper back. No spider nevus, palmar erythema, mucosal lesion, neither hepatosplenomegaly were noted. Dermoscopy revealed tortuous/arborizing vessels and diffuse brownish pigmentation (Fig. 1b). The leucocyte count was $10.2 \times 10^9/L$ with 90% neutrophils. Biochemi-

cal examination showed elevated alanine (86.5 U/L) and aspartate aminotransferases (69.9 U/L), and normal coagulation function, glucose, lipids, estradiol, and testosterone. HBsAg, HBeAg, and PreS1Ag were positive, but anti-nuclear antibody was negative.

Light Microscopy displayed an unremarkable epidermis with basal hyperpigmentation, capillary proliferation, and dilated capillaries with mild infiltration of perivascular lymphohistiocytes in the upper dermis (Fig. 2). Giemsa stain and CD117 immunostaining demonstrated a few mast cells (Fig. 3a). Melan-A and S100 immunostaining found normal melanocytes in the epidermis (Fig. 3b). The patient was diagnosed with ABTM, and his lesions remained stable during a 16-month follow-up without specific treatment.

ABTM, Acquired Bilateral Nevoid Telangiectasia (ABNT) and Telangiectasia Macularis Multiplex Acquisita (TMMA) are three newly described Acquired Bilateral Telangiectasia (ABT) in Korea and China. The causative factors include CLD, hypertension, diabetes, smoking, and so on, but true pathomechanism remains elusive. Both ABTM and ABNT are overwhelming in Koreans, while TMMA seems to be peculiar in Chinese. They frequently affect middle-aged men and are often associated with underlying diseases (especially CLD).^{1–5} Clinically, ABTM features two lesional components (brown pigmentation and telangiectasia) mostly on upper arms, ABNT manifests as superficial telangiectasia on the upper body, and TMMA presents as crops of telangiectatic vessels superimposed on erythematous macules on the arms and trunk.^{1–5} The widespread telangiectasia or trunk involvement are liable to have associated CLD.^{1,5} Histologically, the key features of ABTM, ABNT, and TMMA are respectively dermal telangiectasias with epidermal hyperpigmentation; dermal telangiectasia with normal epidermis; and mild perivascular lymphocytic infiltration with or without telangiectasia.^{1–5} Absence of dermal telangiectasia might be due to vasoconstriction induced by epinephrine in local anesthetics.⁵ Collectively, the clinicopathological characteristics of these three ABT have not been well defined because of small samples, relatively heterogeneous patients, and clinical/morphological resemblance among the three diseases.¹ Even if there are some histological differences: epidermal pigmentation, perivascular lymphocytic infiltrate, and dermal telangiectasia, they are minimal.

☆ How to cite this article: Zhang Z-W, Wu H, Tang K-F, Fan Y-M. Clinicodermoscopic and immunohistochemical observation of hepatitis B virus-associated acquired bilateral telangiectatic macules in a Chinese man. *An Bras Dermatol.* 2021;96:791–3.

☆☆ Study conducted at the Department of Dermatology, Affiliated Hospital of Guangdong Medical University, Zhanjiang, Guangdong, China.

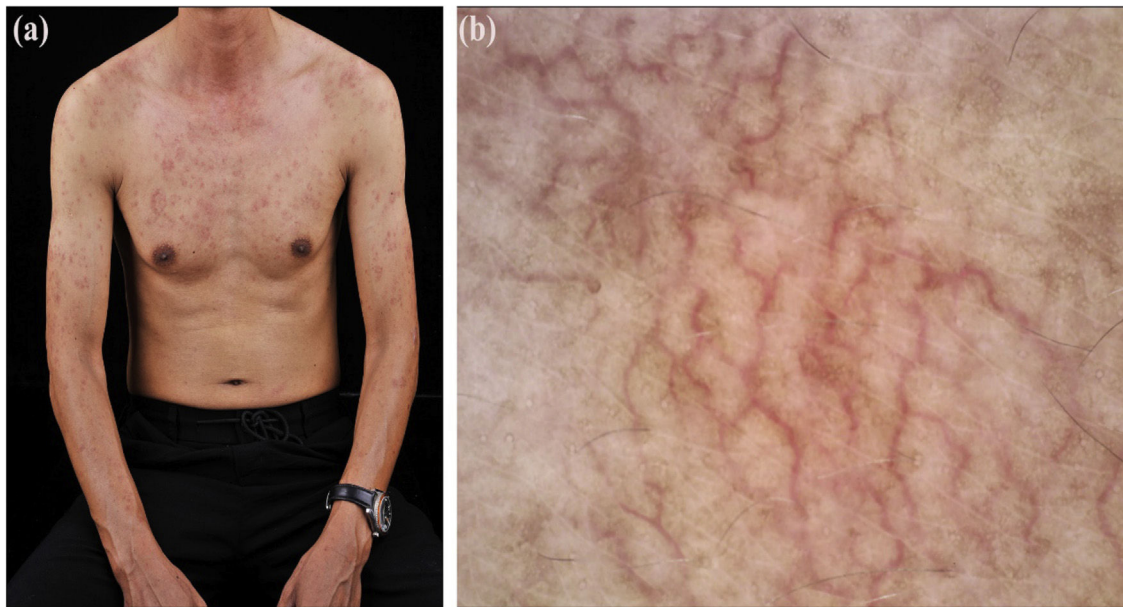


Figure 1 Clinicrodermoscopic features of ABTM: (a), Telangiectatic erythematous macules on the chest and upper limbs. (b), Dermoscopy revealing tortuous/arborizing vessels and diffuse brownish pigmentation on the chest ($\times 30$).

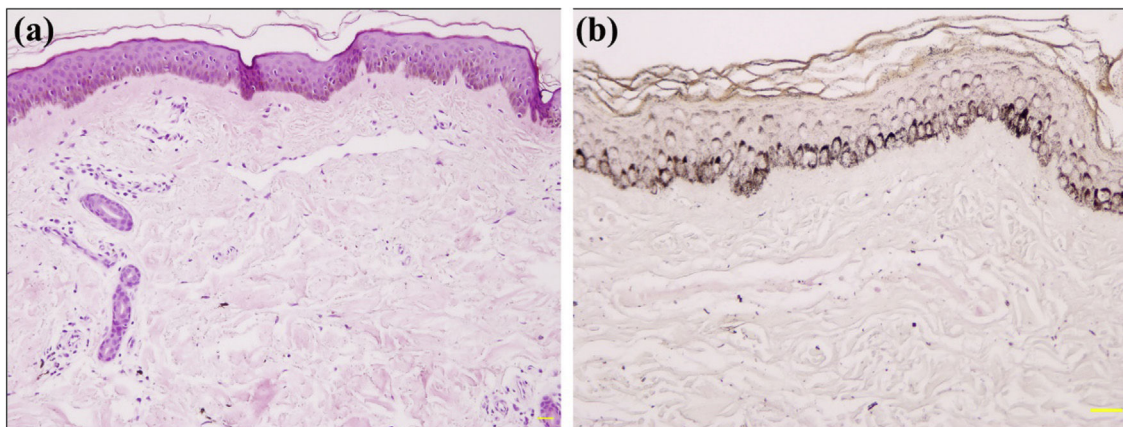


Figure 2 Histopathology of ABTM: (a), Basal hyperpigmentation, capillary proliferation, and dilated capillaries with mild infiltration of perivascular lymphohistiocytes in the upper dermis (Hematoxylin & eosin, $\times 100$). (b), Hyperpigmentation in the basal layer of epidermis (Fontana-Masson, $\times 200$).

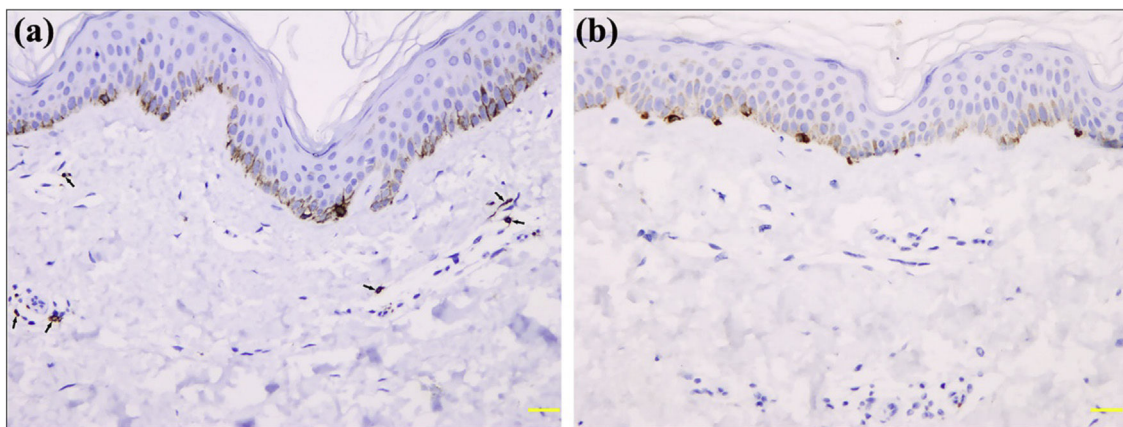


Figure 3 Immunohistochemistry of mastocytes and melanocytes in ABTM: (a), A few CD117 positive mast cells (arrows) around the dilated capillaries in the papillary dermis ($\times 200$). (b), Normal Melan-A positive melanocytes in the epidermis ($\times 200$).

They are hard to distinguish from each other in clinical practice because of their clinicopathological similarity or overlap. In line with the opinion of Kim et al., we believe that the three disorders are the same disease entity and propose the use of the Latin term ‘‘telangiectasia macularis multiplex acquisita’’.¹ In addition, Telangiectasia Macularis Eruptiva Perstans is similar to these entities, but histologically the presence of a mastocyte infiltrate can differentiate them.¹

Dermoscopy displayed brown pigmentation, linear-irregular vessels, and angiod streak pattern in ABTM, corresponding to basal hyperpigmentation and dermal telangiectasia, respectively. Angiod streak pattern was defined as a central arteriole with superficial radiating small vessels, maybe representing a minor form of spider angioma.¹ The severity and prevalence of angiod streak patterns were higher in ABTM patients with CLD than in those without CLD, but it was absent in our case.¹

In conclusion, dermoscopy is useful to observe the inconspicuous pigmentation and telangiectasia in ABTM, but the potential value of the angiod streak pattern for the evaluation of underlying CLD remains to be verified. There is no convincing evidence to create several different names for ABT.

Financial support

None declared.

Authors' contributions

Zi-Wei Zhang: Conception and planning of the study; obtaining, analyzing, and interpreting the data; writing of the manuscript.

Hao Wu: Planning of the study; obtaining, analyzing, and interpreting the data; writing of the manuscript.

Ke-Feng Tang: Obtaining, analyzing, and interpreting the data.

Yi-Ming Fan: Conception and planning of the study, obtaining, analyzing, and interpreting the data, critical revision of the manuscript, and approval of its final version.

Conflicts of interest

None declared.

References

1. Kim GW, Shin K, Kim TW, You HS, Jin HJ, Shim WH, et al. The importance of dermoscopy for the diagnosis of acquired bilateral telangiectatic macules: the angiod streak pattern reveals underlying chronic liver disease. *J Eur Acad Dermatol Venereol.* 2018;32:1597–601.
2. Yang JY, Kim SM, Kim YC. Pulsed dye laser therapy in patients with acquired bilateral telangiectatic macules. *Eur J Dermatol.* 2018;28:99–100.
3. Park JH, Lee DJ, Lee YJ, Jang YH, Kang HY, Kim YC. Acquired bilateral telangiectatic macules: a distinct clinical entity. *JAMA Dermatol.* 2014;150:974–7.
4. Yao X, Liu Y, Xue Y, Tan C, Chen L, Si H, et al. The first report of acquired bilateral telangiectatic macules in China. *Chin J Derm Venereol.* 2018;32:751–3.
5. Chang CH, Lu PH, Kuo CJ, Yang CH. Telangiectasia macularis multiplex acquisita: a new entity in Chinese populations and an analysis of associated factors. *Int J Dermatol.* 2013;52:426–31.

Zi-Wei Zhang , Hao Wu , Ke-Feng Tang , Yi-Ming Fan *

Department of Dermatology, Affiliated Hospital of Guangdong Medical University, Zhanjiang, Guangdong, China

* Corresponding author.

E-mail: ymfan1963@163.com (Y. Fan).

Received 20 June 2020; accepted 6 August 2020; Available online 27 September 2021

<https://doi.org/10.1016/j.abd.2020.08.027>
0365-0596/ © 2021 Published by Elsevier España, S.L.U. on behalf of Sociedade Brasileira de Dermatologia. This is an open access article under the CC BY license (<http://creativecommons.org/licenses/by/4.0/>).

Pigmented poroma on the scalp clinically mimicking basal cell carcinoma ^{☆,☆☆}



A 73-year-old Japanese woman visited our department complaining of a nodule on the scalp which had appeared four years previously. Physical examination revealed a 12-mm semi-pedunculated black nodule on the left side of the head (Fig. 1). Dermoscopic examination showed large blue-gray ovoid nest-like structures, irregularly dilated vessels, and

erosions. Histopathological examination showed a nodular tumor extending from the epidermis into the mid-dermis (Fig. 2). The tumor was composed of small round cells that had a high nucleocytoplasmic ratio, with small pores, which are features of sweat duct differentiation features of poroid differentiation into small ductal structures (Fig. 3). There were no histopathological features suggestive of basal cell carcinoma (BCC). Some of the tumor cells contained melanin granules, and an increased number of melanocytes, confirmed by HMB-45 staining and MART-1 staining, was observed within the nests. Also, many melanophages were observed in the stroma. After making a diagnosis by punch biopsy, the nodule was removed under local anesthesia.

Eccrine poroma is a benign adnexal tumor mainly composed of poroid cells and often present as a reddish nodule. While eccrine poroma does not appear to have a bias for occurrence between races, pigmented variants

[☆] How to cite this article: Ishikawa M, Ohtsuka M, Yamamoto T. Pigmented poroma on the scalp clinically mimicking basal cell carcinoma. *An Bras Dermatol.* 2021;96:793–5.

^{☆☆} The study was conducted in Department of Dermatology, Fukushima Medical University, Fukushima, Japan.