

gested that reflectance confocal microscopy may be useful for diagnosing pigmented eccrine poroma, biopsy is still essential for the diagnosis in order to avoid misdiagnosis and overtreatment.⁵ In conclusion, considering the lack of established specific dermoscopic criteria for pigmented eccrine poroma, pigmented eccrine poroma on the scalp should be biopsied for histopathologic confirmation of the diagnosis.

Financial support

None.

Authors' contributions

Masato Ishikawa: Designed the study; performed the research and contributed to analysis and interpretation of data; wrote the initial draft of the manuscript; read and approved the final version of the manuscript.

Mikio Ohtsuka: Performed the research and contributed to analysis and interpretation of data; read and approved the final version of the manuscript.

Toshiyuki Yamamoto: Designed the study; assisted in the preparation of the manuscript; read and approved the final version of the manuscript.

Conflicts of interest

None declared.

References

1. Kuo HW, Ohara K. Pigmented eccrine poroma: a report of two cases and study with dermatoscopy. *Dermatol Surg.* 2003;29:1076–9.
2. Minagawa A, Koga H. Dermoscopy of pigmented poromas. *Dermatology.* 2010;221:78–83.
3. Ito K, Ansai S, Kimura T. A clinicopathological analysis of 421 cases of poroid cell neoplasms 4th report: Histopathological subfindings. *J Dermatol.* 2009;119:173–82.
4. Kassuga LE, Jeunon T, Sousa MA, Campos-do-Carmo G. Pigmented poroma with unusual location and dermoscopic features. *Dermatol Pract Concept.* 2012;2:203a7.
5. Bombonato C, Piana S, Moscarella E, Lallas A, Argenziano G, Longo C. Pigmented eccrine poroma: dermoscopic and confocal features. *Dermatol Pract Concept.* 2016;6:59–62.

Masato Ishikawa *, Mikio Ohtsuka , Toshiyuki Yamamoto 

Department of Dermatology, Fukushima Medical University, Fukushima, Japan

* Corresponding author.

E-mail: ishimasa@fmu.ac.jp (M. Ishikawa).

Received 15 July 2020; accepted 6 August 2020; Available online 24 September 2021

<https://doi.org/10.1016/j.abd.2020.08.028>

0365-0596/ © 2021 Sociedade Brasileira de Dermatologia.

Published by Elsevier España, S.L.U. This is an open access article under the CC BY license (<http://creativecommons.org/licenses/by/4.0/>).

Safety and efficacy of an interleukin 12/23 inhibitor in a patient with constitutional neutropenia and psoriasis vulgaris^{☆,☆☆}



Dear Editor,

Psoriasis is a chronic, immune-mediated and complex inflammatory disease. The immunopathogenesis of the disease involves interferon-gamma (IFN-gamma), tumor necrosis factor (TNF), and specific interleukins (ILs) that coordinate the interaction between inflammatory cells and keratinocytes.¹

IL inhibitors represent a new group of biological agents with greater specificity for the treatment of psoriasis, as they selectively target inflammatory pathways.¹

Ustekinumab is a fully human monoclonal antibody that binds with high affinity and specificity to the p40 protein subunit, shared by cytokines IL-12 and IL-23.^{2,3} Its action prevents the binding of IL-12 and IL-23 to their receptor, blocking the Th1 and Th17-mediated inflammatory pathways.^{3,4}

Benign constitutional neutropenia is an asymptomatic condition characterized by mild chronic neutropenia (neutrophil count < 1500/mm³) in patients with no history of recurrent infections and no secondary causes.⁵ As these patients are susceptible to infections, the use of immunobiological agents in this population may require special care regarding their safety. There are no reports in the literature on the use and safety of IL-12 and IL-23 inhibitors in these patients.

A 44-year-old dark-skinned male patient started follow-up at a dermatology referral service 10 years ago due to severe psoriasis, without joint involvement. He had a previous diagnosis of familial constitutional leukopenia 17 years ago, with a mean leukocyte count of 2600 mm³

[☆] How to cite this article: Starek JV, Bechara CSR, Dultra MRR, Krakheche JM. Safety and efficacy of an interleukin 12/23 inhibitor in a patient with constitutional neutropenia and psoriasis vulgaris. *An Bras Dermatol.* 2021;96:795–7.

^{☆☆} Study conducted at the Complexo Hospitalar Padre Bento de Guarulhos, Guarulhos, SP, Brazil.

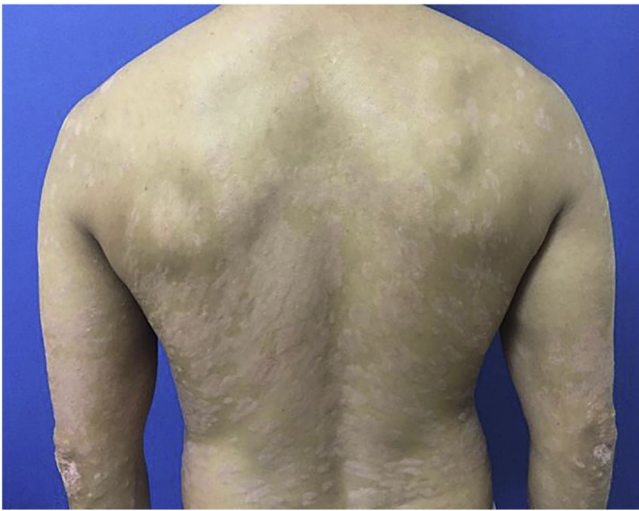


Figure 1 PASI 12.9, erythematous-scaling plaques.

and neutrophil count of 770 mm^3 . He had been previously treated with acitretin, topical medications and undergone around 400 phototherapy sessions, but persisted with erythematous-desquamative plaques on the lower limbs, upper limbs, trunk, and scalp, with progressive worsening. In 2017, due to treatment refractoriness, with a Dermatological Life Quality Index (DLQI) of 13, Psoriasis Area and Severity Index (PASI) of 12.9 (Fig. 1) and, considering the constitutional neutropenia, the use of ustekinumab was proposed with the caveat of undergoing monthly monitoring and withdrawing the treatment if the patient had a neutrophil count $< 500/\text{mm}^3$.

After undergoing the initial tests before starting the immunobiological treatment, which were all within the normal range, treatment with ustekinumab 45 mg was introduced, with the induction phase taking place in weeks 0 and 4 and then every 12 weeks, associated with calcipotriol, twice a day. The patient showed significant lesion improvement after 12 weeks, with residual macules only and currently with PASI 0 (Fig. 2). The patient continues to use the medication up to the present date, without any adverse effects or infections during the entire period (3 years of use). He maintained stable absolute neutrophil values, demonstrating the safety of the medication.

Evidence indicates that neutropenia during therapy with ustekinumab is rare, and when it occurs it is mild; therefore, periodic monitoring is recommended.⁴ As our patient already had a diagnosis of constitutional neutropenia, this adverse effect was the most feared one and the laboratory follow-up was performed monthly, and no relevant alterations were noted after 3 years of drug use.

Financial support

None declared.

Authors' contributions

Jessica Vianna Starek: Approval of the final version of the manuscript; design and planning of the study; drafting and

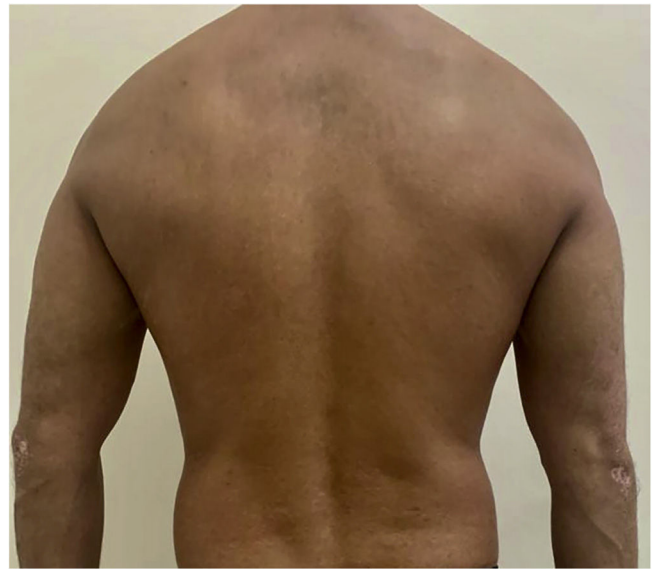

Figure 2 PASI 0, discrete residual macules after 3 years of treatment.

editing of the manuscript; collection, analysis and interpretation of data; critical review of the literature; critical review of the manuscript.

Mariana Reis and Rocha Dultra: Approval of the final version of the manuscript; drafting and editing of the manuscript; collection, analysis, and interpretation of data; critical review of the literature; critical review of the manuscript.

Cristina Santos Ribeiro Bechara: Approval of the final version of the manuscript; design and planning of the study; drafting and editing of the manuscript; collection, analysis, and interpretation of data; critical review of the manuscript.

Juliana de Moraes Fernandes Krakheche: Approval of the final version of the manuscript; design and planning of the study; collection, analysis, and interpretation of data; effective participation in research orientation; intellectual participation in propaedeutic and/or therapeutic conduct of the studied cases; critical review of the literature; critical review of the manuscript.




Conflicts of interest

None declared.

References

1. Bilal J, Berlinberg A, Bhattacharjee S, Trost J, Riaz IB, Kurtzman DJB. A systematic review and meta-analysis of the efficacy and safety of the interleukin (IL)-12/23 and IL-17 inhibitors ustekinumab, secukinumab, ixekizumab, brodalumab, guselkumab and tildrakizumab for the treatment of moderate to severe plaque psoriasis. *J Dermatolog Treat.* 2018;29:569–78.
2. Wilder EG, Patel M, Hebler K, Menter A. Ustekinumab treatment for psoriasis in 119 patients maintained on therapy for a minimum of one year: a review. *J Drugs Dermatol.* 2014;13:905–10.

- Lopez-Ferrer A, Laiz A, Puig L. The safety of ustekinumab for the treatment of psoriatic arthritis. *Expert Opin Drug Saf.* 2017;16:733–42.
- Leonardi CL, Kimball AB, Papp KA, Yeilding N, Guzzo C, Wang Y, et al. Efficacy and safety of ustekinumab, a human interleukin-12/23 monoclonal antibody, in patients with psoriasis: 76-week results from a randomised, double-blind, placebo-controlled trial (PHOENIX 1). *Lancet.* 2008;371:1665–74.
- Souto Filho JTD, Portugal RD, Nucci M. Effect of circadian variation on neutrophil mobilization to the peripheral blood in benign constitutional neutropenia. *Exp Hematol.* 2019;69:22–6.

Jéssica Vianna Starek ^{a,*},
Cristina Santos Ribeiro Bechara ^a,
Mariana Reis e Rocha Dultra ^a,
Juliana de Moraes Fernandes Krakheche ^b

^a *Complexo Hospitalar Padre Bento de Guarulhos, Guarulhos, SP, Brazil*

^b *General Dermatology and Severe Psoriasis Outpatient Clinic, Complexo Hospitalar Padre Bento de Guarulhos, Guarulhos, SP, Brazil*

* Corresponding author.

E-mail: jessicastarek@gmail.com (J.V. Starek).

Received 18 October 2020; accepted 9 November 2020;
Available online 17 September 2021

<https://doi.org/10.1016/j.abd.2020.11.010>

0365-0596/ © 2021 Sociedade Brasileira de Dermatologia.

Published by Elsevier España, S.L.U. This is an open access article under the CC BY license (<http://creativecommons.org/licenses/by/4.0/>).

Tumoral melanosis without metastasis: a report after three years of follow-up^{☆,☆☆}



Dear Editor,

Tumoral melanosis is a rare clinical manifestation of a completely regressed melanoma, usually represented by a pigmented lesion clinically suspected of invasive melanoma. The histopathological examination shows a dense dermal melanophage infiltrate but no atypical melanocytes.¹ The prognosis for this unusual entity is uncertain, but metastases have been described during follow-up or even at the diagnosis.²

This is the report of a white female patient, aged 56 years, with no previous history of sunburns and with a dark pigmented lesion on the back, measuring 1.2 cm in diameter and showing a hypopigmented halo, which was detected during medical consultation and without a history of growth. Dermoscopy disclosed areas of peppering in the periphery, irregular edges, and a bluish-gray veil (Fig. 1). No hardened or enlarged lymph nodes were found during palpation.

An excisional biopsy with a 2-mm margin was performed, considering the hypothesis of melanoma, and the histopathological examination revealed multiple aggregates of melanophages in the reticular dermis (Clark III), better observed after counterstaining with Giemsa (Figs. 2 and 3). The diagnosis of tumoral melanosis was established and a choice was made for enlargement with margins measuring 2 cm in diameter. Clinical examination and total body computed tomography did not disclose metastatic lesions. An abdominal and lymph node ultrasonography was performed, which did not disclose the presence of enlargement or signs

of metastasis. The patient was maintained under clinical follow-up every three months, for three consecutive years, with no signs of local recurrence of the lesion or metastasis, confirmed by clinical and ultrasonographic examination.

Regression is a common occurrence in melanocytic neoplasias and is expected to occur in approximately 30% of cases. It usually occurs focally and seems to have little or no effect on the prognosis of an excised melanoma. However, extensive areas of regression are associated with a worse prognosis.³ Since tumoral melanosis represents com-

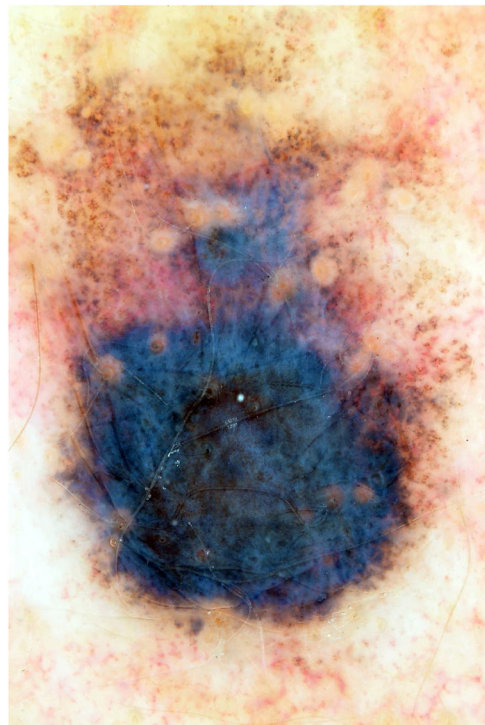


Figure 1 Blackish lesion, measuring 1.2 cm in diameter, with a hypopigmented halo; dermoscopy shows irregular borders and a bluish-gray veil.

[☆] How to cite this article: Miola AC, Esposito ACC, Stolf HO, Miot AA. Tumoral melanosis without metastasis: a report after three years of follow-up. *An Bras Dermatol.* 2021;96:797–8.

^{☆☆} Study conducted at the Hospital das Clínicas, Faculty of Medicine, Universidade Estadual Paulista, Botucatu, SP, Brazil.