

## References

1. Theos A, Korf BR, American College of Physicians; American Physiological Society. Pathophysiology of neurofibromatosis type 1. *Ann Intern Med.* 2006;144:842–9.
2. Kaufmann D, Wiandt S, Vesper J, Krone W. Increased melanogenesis in cultured epidermal melanocytes from patients with neurofibromatosis 1 (NF1). *Hum Genet.* 1991;87:144–50.
3. Shin JH, Kim MJ, Cho S, Whang KK, Hahm JH. A case of giant congenital nevocytic nevus with neurotization and onset of vitiligo. *J Eur Acad Dermatol Venereol.* 2002;16:384–6.
4. Gach JE, Carr RA, Charles-Holmes R, Harris S. Multiple congenital melanocytic naevi presenting with neurofibroma-like lesions complicated by malignant melanoma. *Clin Exp Dermatol.* 2004;29:473–6.
5. Karmakar S, Reilly KM. The role of the immune system in neurofibromatosis type 1-associated nervous system tumors. *CNS Oncol.* 2017;6:45–60.

Sidharth Tandon , Ajeet Singh \*, Pooja Arora ,  
Ram Krishan Gautam 

*Dermatology Department, PGIMER & Dr. Ram Manohar Lohia Hospital, New Delhi, India*

\* Corresponding author.

E-mail: [a.ajityadav@gmail.com](mailto:a.ajityadav@gmail.com) (A. Singh).

Received 9 March 2018; accepted 25 October 2018

<https://doi.org/10.1016/j.abd.2019.09.003>  
0365-0596/

© 2019 Sociedade Brasileira de Dermatologia. Published by Elsevier España, S.L.U. This is an open access article under the CC BY license (<http://creativecommons.org/licenses/by/4.0/>).

## Hibernoma: case report of a rare lipomatous tumor<sup>☆,☆☆</sup>

Dear Editor,

We report the case of a 24-year-old female, Fitzpatrick phototype V, referred to our Dermatology Department for an asymptomatic mass in her left dorsal region. The patient reported a slow growth of this mass over several years. Physical examination revealed a palpable, soft, subcutaneous tumor in the left dorsal region, without apparent involvement of the superjacent skin, which was painless on palpation. The remainder of the examination was otherwise normal.

A high-resolution thoracic computed tomography performed one year before, in the context of an episode of asthma exacerbation, had revealed a large, low-density, subcutaneous nodularity in the referred topography (Fig. 1A). Also, an ultrasound-guided core needle biopsy (Fig. 1B) of this well-defined, slightly hyperechoic, subcutaneous mass identified a neoplasm of globular cells, some with multi-vacuolated cytoplasm and others with granular, eosinophilic cytoplasm, without nuclear atypia.

Considering this, we performed a complete surgical tumor resection, under local anesthesia, in an uneventful procedure (Fig. 2A). The tumor measured approximately 60 × 50 × 20 mm, had a gelatinous external surface and, on section, showed a soft consistency and a brownish coloration (Fig. 2A and B). The histopathological examination revealed a hypodermic tumor, involved by a thin fibrous capsule, constituted by adipocytes with granular, eosinophilic cytoplasm, without cytologic atypia, numerous multi-vacuolated adipocytes and some uni-vacuolated cells, establishing the definite diagnosis of a hibernoma (Fig. 3). The patient recov-

ered fully after surgery, without tumor recurrence after six months of follow-up.

Hibernomas are rare, benign soft-tissue tumors arising from vestigial brown fat, which can be located in the subcutaneous tissue, the skeletal muscle, or the intermuscular fascia.<sup>1,2</sup> There are four histological variants of hibernoma: typical (82%), myxoid (9%), lipoma-like (7%), and spindle-cell (2%).<sup>1</sup> Hibernomas vary in size (1–24 cm, average dimension 9.3 cm) and location, occurring most commonly in the thigh, peri- and interscapular region, neck, arm, abdominal cavity, and retroperitoneum, and they are typically highly vascularized.<sup>1,3–5</sup> They are most often diagnosed in adults (mean age 38 years).<sup>1</sup>

These lipomatous tumors generally present either as slow-growing, painless, soft, palpable and mobile masses, or as incidentalomas in imaging studies.<sup>1,3–5</sup> Symptoms secondary to compression of adjacent structures can also develop due to their growth.<sup>1,3,4</sup> Differential diagnosis is not always straightforward, and includes not only benign soft-tissue neoplasms (like atypical lipomas, hemangiomas, and angiolipomas) but also malignant, aggressive tumors (namely well-differentiated liposarcomas, myxoid liposarcomas, and rhabdomyosarcomas).<sup>1,2</sup> In fact, hibernomas can mimic these other tumors clinically, imagiologically, and even histologically, considering some similar features in biopsy specimens.<sup>1–5</sup>

Histopathological examination of the tumor following complete surgical excision, which is curative, is essential for confirming the diagnosis.<sup>1,4,5</sup>

## Financial support

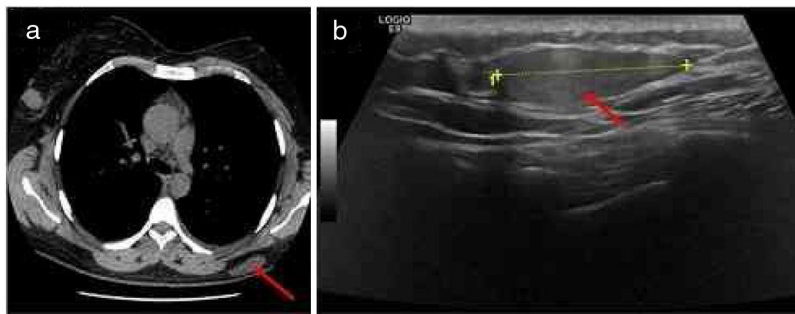
None declared.

## Author's contribution

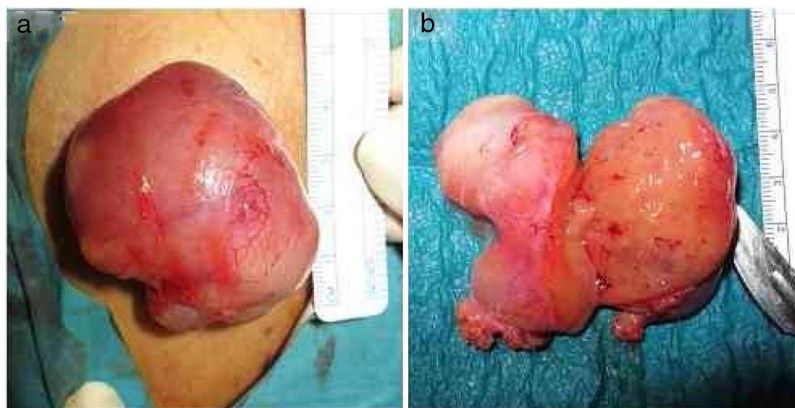Margarida Moura Valejo Coelho: Approval of the final version of the manuscript; elaboration and writing of the manuscript; obtaining, analyzing and interpreting the data; effective participation in research orientation; intellectual participation in propaedeutic and/or therapeutic conduct

<sup>☆</sup> How to cite this article: Valejo Coelho MM, João A, Fernandes C. Hibernoma: case report of a rare lipomatous tumor. *An Bras Dermatol.* 2019;94:626–8.

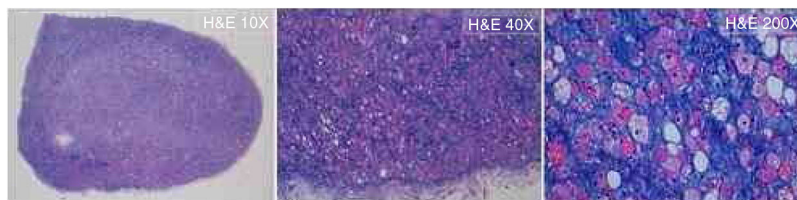
<sup>☆☆</sup> Study conducted at the Department of Dermatology and Venerology, Centro Hospitalar Universitário de Lisboa Central, Lisbon, Portugal.



**Figure 1** Imagiological features of the tumor: A, High-resolution thoracic computed tomography revealing a large, low-density, subcutaneous nodule in the left dorsal region (red arrow); B, Ultrasound revealing a well-defined, slightly hyperechoic, subcutaneous mass in the left dorsal region (red arrow).



**Figure 2** Macroscopic features of the tumor: A, During surgical tumor resection, under local anesthesia; B, After complete excision, the tumor measured approximately 60 × 50 × 20 mm, had a gelatinous external surface and, on section, showed a soft consistency and a brownish coloration.



**Figure 3** Microscopic features of the tumor: The histopathological examination (Hematoxylin & eosin: ×10, ×40, ×200) of the surgical specimen revealed a hypodermic tumor, involved by a thin fibrous capsule, constituted by adipocytes with granular, eosinophilic cytoplasm, without cytologic atypia, numerous multi-vacuolated adipocytes, and some uni-vacuolated cells, establishing the definitive diagnosis of hibernoma.

of the case studied; critical review of the literature; critical review of the manuscript.

Alexandre João: Approval of the final version of the manuscript; obtaining, analyzing and interpreting the data; intellectual participation in propaedeutic and/or therapeutic conduct of the case studied; critical review of the manuscript.

Cândida Fernandes: Approval of the final version of the manuscript; obtaining, analyzing and interpreting the data; intellectual participation in propaedeutic and/or therapeutic conduct of the case studied; critical review of the manuscript.




### Conflicts of interest

None declared.

### References

1. Furlong MA, Fanburg-Smith JC, Miettinen M. The morphologic spectrum of hibernoma: a clinicopathologic study of 170 cases. *Am J Surg Pathol.* 2001;25:809–14.
2. JR Goldblum. Soft Tissues. In: Goldblum JR, Lamps LW, McKenney JK, Myers JL. Rosai and Ackerman's surgical pathology. 11th ed. Philadelphia: Elsevier; 2018. 1810–915.

3. Murphey MD, Carroll JF, Flemming DJ, Pope TL, Gannon FH, Kransdorf MJ. From the archives of the AFIP: benign musculoskeletal lipomatous lesions. *Radiographics*. 2004;24:1433–66.
4. Daubner D, Spieth S, Pablik J, Zöphel K, Paulus T, Laniado M. Hibernoma – two patients with a rare lipoid soft-tissue tumour. *BMC Med Imaging*. 2015;15:4.
5. Shackelford RE, Al Shaarani M, Ansari J, Wei E, Cotelingam J. A twenty-four-year-old woman with left flank lipoma-like hibernoma. *Case Rep Oncol*. 2017;10:438–41.

Margarida Moura Valejo Coelho \*, Alexandre João , Cândida Fernandes 

Department of Dermatology and Venereology, Centro Hospitalar Universitário de Lisboa Central, Lisbon, Portugal

\* Corresponding author.

E-mail: [margarida.m.v.coelho@chlc.min-saude.pt](mailto:margarida.m.v.coelho@chlc.min-saude.pt) (M.M. Valejo Coelho).

Received 23 August 2018; accepted 6 November 2018

<https://doi.org/10.1016/j.abd.2019.09.018>  
0365-0596/

© 2019 Published by Elsevier España, S.L.U. on behalf of Sociedade Brasileira de Dermatologia. This is an open access article under the CC BY license (<http://creativecommons.org/licenses/by/4.0/>).

## Urticaria multiforme: a case report in an infant<sup>☆,☆☆</sup>

Dear Editor,

Urticaria multiforme (UM) is an uncommon benign cutaneous hypersensitivity that occurs mainly in pediatric patients.<sup>1,2</sup> It is characterized by annular lesions with a violaceous center, and may be accompanied by short-term fever, as well as by hand and foot edema.<sup>2,3</sup> It is a poorly recognized condition, mainly due to lack of reports in the literature. Furthermore, it is an important differential diagnosis for erythema multiforme.

A female infant was born at 31 weeks due to intrauterine growth restriction. After receiving the meningococcal and pneumococcal vaccines when she was 4 months old, annular macules with erythematous borders and red-frosted centers appeared (Fig. 1). The lesions presented an ephemeral character (24 h), with new macules appearing concomitantly. Due to age, it was not possible to evaluate pruritus. The diagnostic hypotheses were urticaria multiforme and childhood annular erythema. A biopsy was conducted, revealing preserved epidermis, a superficial and deep perivascular and interstitial inflammatory lymphohistiocytic infiltrate permeated with some eosinophils. There was no sign of vasculitis, corroborating with the diagnosis of urticaria multiforme (Figs. 2 and 3). Antihistamine treatment (hydroxyzine 0.5 mg/kg every 12 h) was started. After ten days, the condition resolved completely, without residual lesions.

Originally described in 1997 by Tamayo-Sanchez et al. under the name of acute annular urticaria,<sup>1</sup> it had its name changed to urticaria multiforme in 2007 due to clinical similarity with erythema multiforme,<sup>2</sup> as described by Shah et al., when the authors reported 19 of these cases. They also proposed that this condition is a variant of common urticaria, since the patients presented pruritus and dermatographism.<sup>1,2</sup>

With few cases in the literature, the etiology is poorly understood. In most cases there is a temporal relationship with infections (mycoplasma, adenovirus, streptococci, Epstein–Barr), medications (mainly antibiotics), and vaccinations. In 2016, Sempau et al. found an association with previous use of amoxicillin.<sup>3</sup> Specifically in neonates, there has been proven infection by herpes virus 6, and decreased viral load accompanied by clinical improvement of the patient.<sup>4</sup>

The most affected age range is between 4 months and 4 years, although newborns and adolescents may also develop the condition. Cutaneous lesions begin as urticarial lesions that rapidly expand in a centrifugal manner and become annular, forming coalescent polycyclic plaques with violet

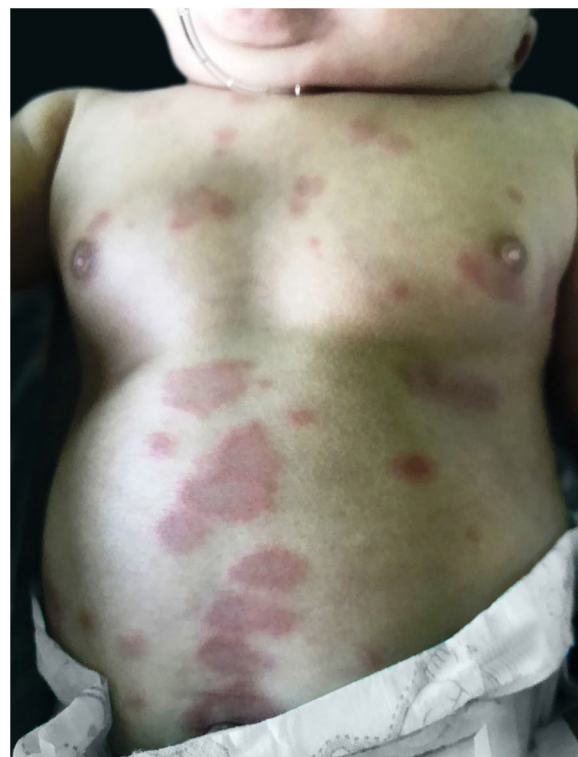

Figure 1 Erythematous annular plaques with lighter centers in the abdomen.

<sup>☆</sup> How to cite this article: Luce MCA, Souza BC, Camargo MFVC, Valente NYS. Urticaria multiforme: a case report in an infant. *An Bras Dermatol*. 2019;94:628–30.

<sup>☆☆</sup> Study conducted at the Hospital do Servidor Público Estadual de São Paulo, São Paulo, SP, Brazil.