



IMAGES IN DERMATOLOGY

Pseudoxanthoma elasticum-like papillary dermal elastolysis in non-exposed skin ☆,☆☆



Nuria Setó-Torrent ^{a,*}, Maribel Iglesias-Sancho ^a, Jorge Arandes-Marcocci ^a,
María Teresa Fernández-Figueras ^b

^a Department of Dermatology, Hospital Universitari Sagrat Cor-Grupo Quirón Salud, Barcelona, Spain

^b Department of Pathology, Hospital Universitari Sagrat Cor-Grupo Quirón Salud, Barcelona, Spain

Received 14 April 2019; accepted 11 August 2019

Available online 12 February 2020

KEYWORDS

Dermis;
Elastic tissue;
Female;
Pseudoxanthoma
elasticum

Abstract Pseudoxanthoma elasticum-like papillary dermal elastolysis is an acquired elastic tissue disorder clinically similar to pseudoxanthoma elasticum in the absence of systemic involvement. Histopathologically, special staining of elastic fibers demonstrates a total or partial band-like loss of elastic fibers in the papillary dermis. Although ultraviolet radiation seems to be one of the main etiological factors in this entity, we report a case of pseudoxanthoma elasticum-like papillary dermal elastolysis on the neck of a woman who wore hijab.

© 2020 Sociedade Brasileira de Dermatologia. Published by Elsevier España, S.L.U. This is an open access article under the CC BY license (<http://creativecommons.org/licenses/by/4.0/>).

A 54-year-old female of Moroccan origin who habitually wears a hijab presented a 2 year history of mildly pruritic lesions on the neck. She denied systemic symptoms and family history of similar findings. Her medical history included mixed anxiety-depressive disorder treated with olanzapine and sertraline. Physical examination revealed

white-to-yellowish millimetric non-follicular papules on the lateral aspects of the neck and supraclavicular fossae (Fig. 1). Dermoscopic examination showed multiple white-colored non-follicular papules, coalescing into plaques with arboriform vessels (Fig. 2). The biopsy showed slight sclerosis of the papillary dermis with neovascularization and a mild inflammatory infiltrate including lymphocytes and some melanophages (Fig. 3). In the same area, van Gieson stain demonstrated a decrease in the number of elastic fibers that were often thin and fragmented (Fig. 4) compatible with pseudoxanthoma elasticum-like papillary dermal elastolysis (PXE-PDE). Cardiac and ophthalmological investigations performed were unremarkable.

PXE-PDE is a rare acquired elastic tissue disorder characterized by non-follicular yellowish papules coalescing into plaques with predilection for neck, supraclavicular fossae

☆ How to cite this article: Setó-Torrent N, Iglesias-Sancho M, Arandes-Marcocci J, Fernández-Figueras MT. Pseudoxanthoma elasticum-like papillary dermal elastolysis in non-exposed skin. An Bras Dermatol. 2020;95:247–9.

☆☆ Study conducted at the Hospital Universitari Sagrat Cor-Grupo Quirón Salud, Barcelona, Spain.

* Corresponding author.

E-mail: nurisetorrent@gmail.com (N. Setó-Torrent).

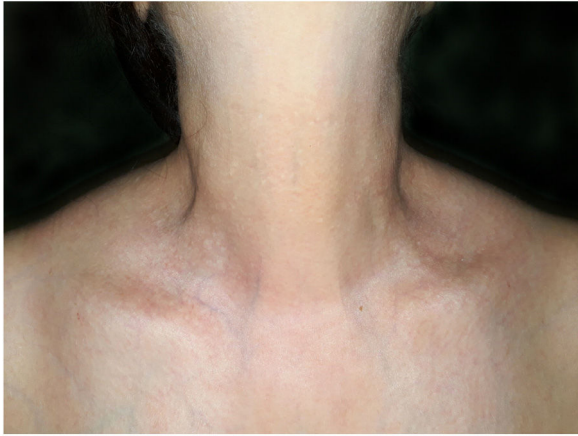

Figure 1 Whitish papules on the neck and supraclavicular fossae.

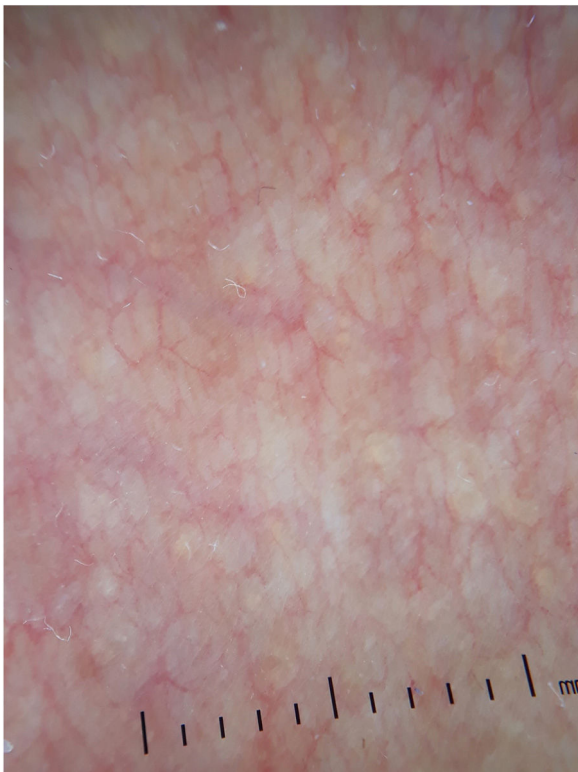


Figure 2 Multiple whitish non-follicular papules, coalescing into plaques with linear vessels, on dermoscopy.

and flexural areas.¹ The lesions are usually asymptomatic, but mild itch is sometimes reported, as seen in our case. To date, it affects exclusively women mostly in middle age² and it is not associated with any systemic involvement. Dermoscopic findings consist of multiple white-colored non-follicular papules, coalescing into plaques with linear vessels.³

Histopathologically, hematoxylin eosin staining does not reveal any specific changes. The focal inflammatory changes present in our case have not been described previously; however, it is presumed that elastic fiber loss could be the result of a transient phenomenon of inflammation. Special staining of elastic fibers with van Gieson or orcein stains

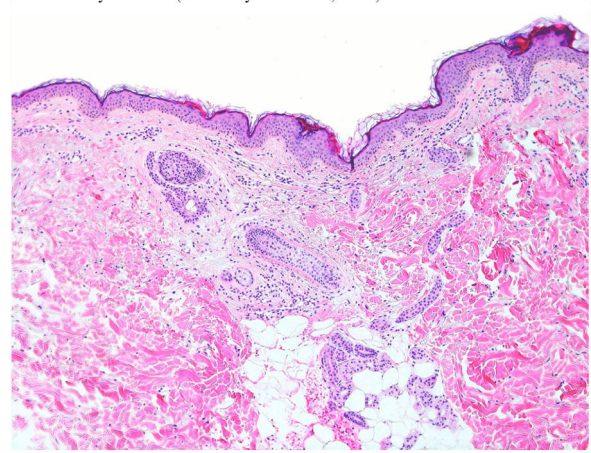


Figure 3 Slight sclerosis of the papillary dermis, neovascularization and a mild inflammatory infiltrate (Hematoxylin & eosin, x100).

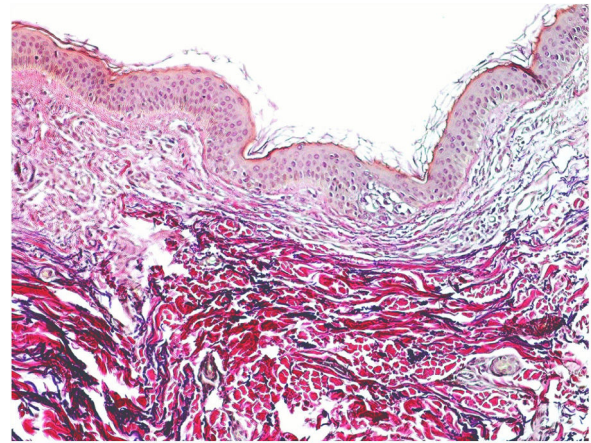


Figure 4 Reduction of elastic fibers in the papillary dermis (van Gieson, x200).

are required to demonstrate a total or partial band-like loss of elastic fibers in the papillary dermis.² Calcification or fragmentation of the elastic fibers is absent. Immunohistochemical studies using monoclonal antibodies against antibody P component can also demonstrate partial or complete loss of elastic fibers in papillary dermis.¹ The presence of melanophages in the papillary dermis constitutes an additional helpful diagnostic feature.⁴

The cause of PXE-PDE remains unclear, and some etiopathogenic theories have been proposed: ultraviolet radiation, intrinsic aging, abnormal elastogenesis, and genetic or inheritable factors.^{1,2} In our case, ultraviolet radiation's etiopathogenic theory is unlikely because the patient wore hijab.

Differential diagnosis of PXE-PDE includes white fibrous papulosis of the neck, mid-dermal elastolysis, and papillary dermal elastosis. Nevertheless, the main differential diagnosis must be established with pseudoxanthoma elasticum (PXE), a hereditary disorder caused by mutation on *ABCC6* gene. Clinically, PXE resembles PXE-PDE, but it appears at a younger age, and it is usually associated with ocular and cardiovascular complications. Histopathologically, PXE

presents fragmentation and calcification of elastic fibers demonstrated with von Kossa stain.

Treatments for PXE-PDE, including topical retinoids, have shown poor results²; however, non-ablative fractional resurfacing laser has demonstrated to be effective in some cases.⁵

Herein we present a case of PXE-PDE in a patient who did not receive UV radiation because she wore hijab. In our opinion, more studies are needed in order to better understand the etiopathogenesis of PXE-PDE. It is important that dermatologists recognize this entity and differentiate it from PXE to avoid unnecessary investigation. Clinicopathologic correlation is important and elastic tissue stains are required to correctly diagnose PXE-PDE.

Financial support

None declared.

Authors' contributions

Nuria Setó Torrent: Approval of the final version of the manuscript; elaboration and writing of the manuscript; intellectual participation in the propaedeutic and/or therapeutic conduct of the studied cases; critical review of the literature; critical review of the manuscript.

Maribel Iglesias Sancho: Approval of the final version of the manuscript; critical review of the manuscript.

Jorge Arandes Marcocci: Approval of the final version of the manuscript; critical review of the manuscript.

María Teresa Fernández Figueras: Approval of the final version of the manuscript; critical review of the manuscript.

Conflicts of interest

None declared.

References

1. Revelles JM, Machan S, Pielasinski Ú, Camacho D, Vallés L, Santonja C, et al. Pseudoxanthoma elasticum-like papillary dermal elastolysis: immunohistochemical study using elastic fiber cross-reactivity with an antibody against amyloid P component. *Am J Dermatopathol.* 2012;34:637–43.
2. Panagou E, Ratynska M, Heelan K. Pseudoxanthoma elasticum-like papillary dermal elastolysis: a case report and review of literature. *Int J Dermatol.* 2019;58:93–7.
3. Ribeiro CP, Abuawad YG, Swiczar BCC, Valente NYS. Pseudoxanthoma elasticum-like papillary dermal elastolysis. *An Bras Dermatol.* 2017;92:897–8.
4. Rongioletti F, Izakovic J, Romanelli P, Lanuti E, Miteva M. Pseudoxanthoma elasticum-like papillary dermal elastolysis: a large case series with clinicopathological correlation. *J Am Acad Dermatol.* 2012;67:128–35.
5. Foering K, Torbeck RL, Frank MP, Saedi N. Treatment of pseudoxanthoma elasticum-like papillary dermal elastolysis with nonablative fractional resurfacing laser resulting in clinical and histologic improvement in elastin and collagen. *J Cosmet Laser Ther.* 2018;20:382–4.