





- Alhuqayl A, Alsaif F, Alsaad A, Alali A. Multiple bilateral Becker's nevus in a Saudi female: a rare presentation. *AME Case Rep.* 2019;3:42.
- Happle R, Koopman RJ. Becker nevus syndrome. *Am J Med Genet.* 1997;68:357-61.
- Cai ED, Sun BK, Chiang A, Rogers A, Bernet L, Cheng B, et al. Postzygotic Mutations in Beta-Actin Are Associated with Becker's Nevus and Becker's Nevus Syndrome. *J Invest Dermatol.* 2017;137:1795-8.
- Antunes-Duarte S, Bouceiro-Mendes R, Fraga A, Soares-de-Almeida L. One person, two bilateral symmetrical giant Becker nevi. *Dermatol Online J.* 2020;26, 13030/qt44x2j7nr.

Li-Wen Zhang , Cun-Huo Jiang , Lin Li ,  
Tao Chen \*

Department of Dermatovenereology, Chengdu Second People's Hospital, Chengdu, Sichuan, China

Corresponding author.

E-mail: 13980427003@163.com (T. Chen).

Received 16 April 2021; accepted 14 May 2021;  
Available online 23 January 2023

<https://doi.org/10.1016/j.abd.2021.05.024>

0365-0596/ © 2022 Published by Elsevier España, S.L.U. on behalf of Sociedade Brasileira de Dermatologia. This is an open access article under the CC BY license (<http://creativecommons.org/licenses/by/4.0/>).

## Case for diagnosis. Hair analysis in a child with delayed psychomotor development and fragile and brittle hair: Trichothiodystrophy<sup>☆</sup>



Dear Editor,

A 4-year-old female child presented to the Dermatology Department with short, thin, and fragile hair since birth (Fig. 1). She also presented important xerosis and eczematous plaques in her back, trunk, and scalp and photosensitivity. The patient also had short stature, severe myopia, delayed psychomotor development, and recurrent respiratory infections.

Examination of the hair under a polarized light microscope showed fine hair and trichoschisis with typical alternating dark and light transverse banding, called "tiger-tail pattern" (Fig. 2) and an irregular surface (Fig. 3).

A genetic study revealed a mutation in the ERCC2 gene.

### What is your diagnosis?

- Xeroderma Pigmentosum
- Trichothiodystrophy
- Menkes disease
- Cockayne syndrome

### Discussion

Based on clinical presentation, trichological and genetic examination, the diagnosis of trichothiodystrophy was established.

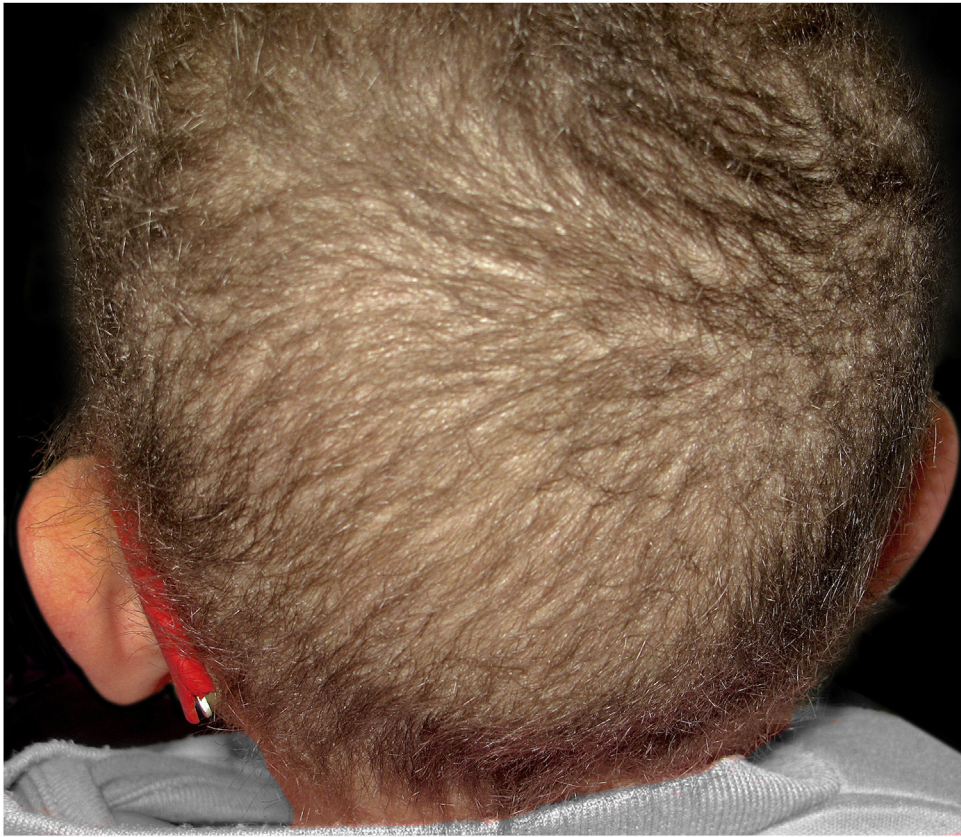Trichothiodystrophy (TTD) is a heterogeneous group of neuroectodermal disorders with an autosomal recessive inheritance, although a few cases with possible X-linked transmission have been reported. The photosensitive form

of TTD is caused by mutations in XPB, XPD, or p8/TTDA genes, which encode subunits of TFIIH transcription/repair factor. Non-photosensitive form of TTD is genetically heterogeneous, being TTDN1 gene the one described in a small proportion of patients.<sup>1</sup> In photosensitive TTD, the most frequently described is XPD (ERCC2) mutation,<sup>2</sup> which is also involved in the pathogenesis of xeroderma pigmentosum (XP) and Cockayne syndrome, although, unlike XP, there is no predisposition to cutaneous malignancies. XP, Cockayne syndrome, and TTD are an example of the phenomenon called clinical heterogeneity, in which mutations in one gene (in this case XPD) may result in distinct diseases or variants.<sup>3</sup>


Clinical features of patients with TTD vary widely in nature and severity, and the single common feature in all patients is fragile hair (short, unruly, fragile hair of the scalp, eyebrows, and eyelashes) due to abnormally low sulfur content. In addition, a wide spectrum of other clinical symptoms that usually affect organs of ectodermal and neuroectodermal origin may be present, such as intellectual and growth retardation, ichthyosis, short stature, decreased fertility, neurologic and ocular abnormalities and, in some cases, recurrent infections,<sup>4</sup> as in the case of our patient. Approximately half of the patients present photosensitivity.<sup>1,4</sup>

When examined under a polarized microscope, hair samples constantly show striking bright and dark transverse banding or "tiger tail pattern", and they often exhibit an undulating, irregular contour in all hairs (differently from pseudo-tiger tail banding).<sup>5,6</sup> Trichoschisis and trichorrhhexis nodosa-like defects are also distinctive hair shaft abnormalities in TTD though not always present. In contrast to TTD, other patients with similar defects in DNA repair and mutations in the XPD gene do not show true "tiger tail banding". A "pseudo-tiger tail banding" can be observed in segments of normal shafts, but the banding pattern is usually less pronounced and less regular than the bright and dark banding observed in TTD patients.<sup>5</sup> In fact, characteristic microscopic hair findings distinguish trichothiodystrophy from other conditions with congenital alopecia or hypotrichosis. For example, patients with Menkes disease typically present "kinky hairs" with twists around their long axis at irregular intervals in the shaft

<sup>☆</sup> Study conducted at the Hospital Regional Universitario de Málaga, Málaga, Spain.



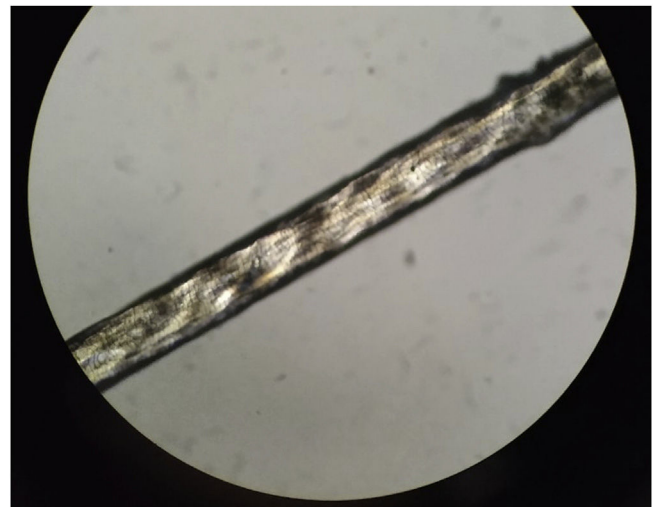
**Figure 1** Short brittle hair easily broken at different lengths.



**Figure 2** Examination of the hair under a polarized microscope: trichoschisis with typical "tiger-tail pattern". Note the alternating dark and light transverse banding.

when observed under a light microscope, also known as pili torti.<sup>7</sup>

In conclusion, analysis of the hair under a polarized microscope is considered a very useful diagnostic marker in trichothiodystrophy since it shares clinical and genetic characteristics with other neuroectodermal syndromes.



**Figure 3** Irregular, undulating hair shaft when examined under light microscopy.

Diagnosis can be made on the basis of clinical and trichological examination with a polarizing and light microscope, although a genetic study may be helpful.

### Financial support

None declared.



## Authors' contributions

Irene López Riquelme: Critical review of the literature; writing of the manuscript; final approval of the final version of the manuscript.

Alberto Andamoyo Castañeda: Critical review of the literature; writing of the manuscript; final approval of the final version of the manuscript.

Elisabeth Gómez Moyano: Intellectual participation in the propaedeutic conduct of the case; final approval of the final version of the manuscript.

Ángel Vera Casaño: Intellectual participation in the propaedeutic conduct of the case; final approval of the final version of the manuscript.

## Conflicts of interest

None declared.

## References

1. Stefanini M, Botta E, Lanzafame M, Orioli D. Trichothiodystrophy: from basic mechanisms to clinical implications. *DNA Repair*. 2010;9:2–10.
2. Lund E, Stein S. Novel ERCC2 mutation in two siblings with trichothiodystrophy. *Pediatr Dermatol*. 2019;36:668–71.
3. Tantcheva-Poó I, Oji V, Has C. A multistep approach to the diagnosis of rare genodermatoses. *J Dtsch Dermatol Ges*. 2016;14:969–86.

4. Faghri S, Tamura D, Kraemer K, DiGiovanna J. Trichothiodystrophy: a systematic review of 112 published cases characterises a wide spectrum of clinical manifestations. *J Med Genet*. 2008;45:609–21.
5. Liang C, Kraemer KH, Morris A, Schiffmann R, Price VH, Meneffee E, et al. Characterization of tiger tail banding and hair shaft abnormalities in trichothiodystrophy. *J Am Acad Dermatol*. 2005;52:224–32.
6. Hansen LK, Wulff K, Brandrup F. Trichothiodystrophy. Hair examination as a diagnostic tool. *Ugeskr Laeger*. 1993;155:1949–52.
7. Smith VV, Anderson G, Malone M, Sebire NJ. Light microscopic examination of scalp hair samples as an aid in the diagnosis of paediatric disorders: retrospective review of more than 300 cases from a single centre. *J Clin Pathol*. 2005;58:1294–8.

Irene López Riquelme \*,  
Alberto Andamoyo Castañeda ,  
Elisabeth Gómez Moyano , Ángel Vera Casaño 

Department of Dermatology, Hospital Regional Universitario de Málaga, Málaga, Spain

\* Corresponding author.

E-mail: [lopezriquelmeirene@uma.es](mailto:lopezriquelmeirene@uma.es) (I. López Riquelme).

Received 23 August 2021; accepted 19 October 2021;  
Available online 14 December 2022

<https://doi.org/10.1016/j.abd.2021.10.015>

0365-0596/ © 2022 Sociedade Brasileira de Dermatologia.

Published by Elsevier España, S.L.U. This is an open access article under the CC BY license (<http://creativecommons.org/licenses/by/4.0/>).

## Giant, aggressive Merkel cell carcinoma of the right arm<sup>☆</sup>



Dear Editor,

In October 2018, a 65-year-old woman consults for a red, hot, painful, edematous lesion on the skin of the right arm.

Within two months of the tumor appearance, its volume increased fourfold (Fig. 1).

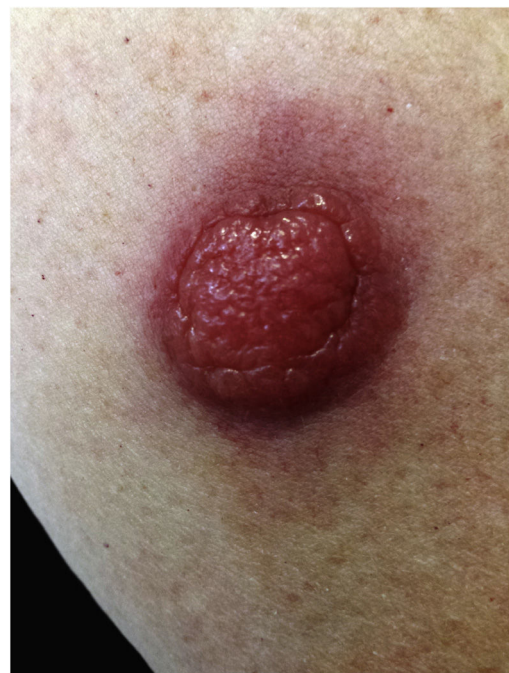The physical examination revealed an erythematous tumor 1.5 cm in diameter, movable in relation to the substrate, and poorly demarcated from the surroundings. History of comorbidities: chronic lymphocytic leukemia B-cell BCLL-PD (treated with Ofatumumab + Chlorambucil, 2008–2009).

The laboratory abnormalities showed a markedly elevated level of leukocytes: 89,600 (N: 4–10).

A 2.0 × 0.7 cm skin section with a subcutaneous tissue thickness of 0.6 cm was taken for evaluation.

In the histopathological examination of the dermis, diffuse infiltration of hyperchromatic atypical cells with a scanty cytoplasm of immunophenotype: CKAE1/3(+)dot-like; CK20(+)dot-like; SYN(+), CgA(±), TTF-1(-), LCA(-), Ki67(+) approx. 90%. The whole picture speaks in favor

of cutaneous neuroendocrine carcinoma (Merkel cell carcinoma) (Fig. 2A and B).



**Figure 1** A large pink, erythematous nodule on the skin of the right arm.

<sup>☆</sup> Study conducted at the Department of Dermatology, Provincial Specialist Hospital in Slupsk, Ustka, Poland.