



RESEARCH LETTER

Association between pemphigus and systemic lupus erythematosus: a systematic review and meta-analysis^{☆☆☆}



Dear Editor,

Pemphigus defines a group of IgG-mediated autoimmune conditions targeting the squamous epithelium of skin and oral mucosa manifesting as intraepidermal blisters and erosions, which can be severely debilitating. The autoimmune etiology and chronicity of pemphigus disorders have spurred investigation into its association with other autoimmune conditions. Some studies note co-existence of pemphigus and systemic lupus erythematosus (SLE). Whether a true association exists or not is unknown. The authors present a systematic review and meta-analysis to assess the association between pemphigus and SLE.

Following PRISMA guidelines, searches were performed using PubMed, Cochrane Central Register of Controlled Trials, Cochrane Database of Systematic Reviews, Ovid MEDLINE, ACP Journal Club, and Database of Abstracts of Review of Effectiveness from their inception dates to August 2019. Search terms used were the following: “pemphigus foliaceus,” “pemphigus vulgaris,” or “pemphigus” in conjunction with “systemic lupus erythematosus,” “lupus,” or “SLE.” Studies included compared SLE cases in pemphigus patients vs. controls. Pemphigus cases included its subtypes (pemphigus vulgaris, pemphigus vegetans, pemphigus foliaceus, pemphigus erythematosus, and drug-induced pemphigus). Studies were excluded if clinical diagnosis was not determined by either direct or indirect immunofluorescence staining or enzyme-linked immunosorbent assay. Case reports, reviews, and studies without controls were also excluded. The odds ratio (OR) was calculated using a random effects model considering the baseline study heterogeneity as assessed with the I statistic. As a supplemental

statistic, the number needed to treat (NNT) was calculated using the OR and the prevalence rate of SLE in North America (241/100,000 people, 0.241%) as a surrogate for the patient expected event rate (PEER).¹ Review Manager v. 5.3 (Cochrane Collaboration – Oxford, United Kingdom) was the statistical software used.

There were 661 references identified; after exclusion of duplicate or irrelevant references, four studies were included (Table 1).^{2–5} A statistically significant association between pemphigus and SLE was noted (OR=2.16, 95% CI 1.09–4.25, $p=0.03$), with heterogeneity ($I^2 = 50\%$) (Fig. 1). The NNT was calculated as 405 using North American SLE prevalence rates as a surrogate for PEER and the OR of 2.16.¹

An autoimmune diathesis describes the association of autoimmune conditions with one another. Although literature describing co-existence of pemphigus with SLE are limited, pemphigus erythematosus (also known as Senear-Usher syndrome), an overlap syndrome between pemphigus vulgaris (PV) and SLE, was described in 1926.⁶ This may highlight an underlying pathophysiologic link between the conditions. Serologic studies demonstrate that one-third of PV cases display ANA-positivity with homogenous pattern, which is associated with active SLE.⁷ Furthermore, a recent genome-wide association study identified novel CD4+ T-cells pathways between pemphigus and SLE in addition to characterizing IRF8 and STAT1 as key regulatory genes.⁸ Both pemphigus and SLE display many antibodies. A proposed mechanism between such autoimmune conditions is epitope spreading, wherein the initial autoinflammatory response exposes new antigens, feeding into a subsequent autoimmune reaction.⁹

Limitations of this study include lack of data concerning immunopathological subtypes, clinical features, disease severity, chronology of diagnoses (*i.e.*, which diagnosis preceded the other), treatment-related information, and a true PEER value to obtain a more accurate NNT. Additionally, different study types, cohort sizes, and patient demographics may influence statistics.

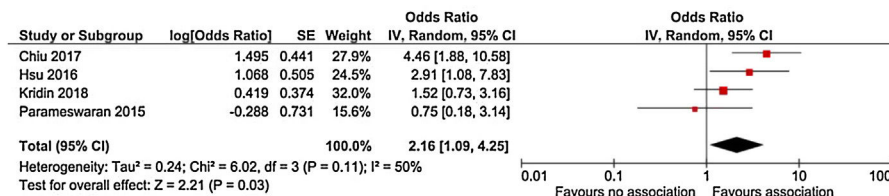
In conclusion, an association was found between pemphigus and SLE, albeit an uncommon clinical occurrence. Nevertheless, clinicians caring for patients with pemphigus should be aware of this association and further research is required to elucidate the molecular basis of this association, more specifically specify its clinical significance and prevalence, and possibly identify optimal therapeutic strategies for patients with coexistence of both conditions.

[☆] How to cite this article: Ramachandran V, Phan K, Smith SD. Association between pemphigus and systemic lupus erythematosus: a systematic review and meta-analysis. An Bras Dermatol. 2021;96:243–5.

^{☆☆} Study conducted at the Department of Dermatology, Liverpool Hospital, Sydney, Australia and at the University of New, South Wales, Sydney, Australia.

Table 1 Characteristics of studies that evaluated the association between pemphigus and systemic lupus erythematosus.

Author, Journal	Title	Location	Design	Number of cases	Number of controls
Chiu, Eur J Dermatol. 2017 Aug 1;27(4):375-381. ²	Comorbid autoimmune diseases in patients with pemphigus: a nationwide case-control study in Taiwan	Taiwan	Case-control	1,998	7,992
Hsu, Br J Dermatol. 2016 Jun; 174(6):1290-8. ³	Comorbidities and inpatient mortality for pemphigus in the United States.*	USA	Cross-sectional	6,406	87,033,305
Kridin, J Am Acad Dermatol. 2017 Dec; 77(6):1174-1175. ⁴	Association between pemphigus and psoriasis: A population-based large-scale study.	Israel	Cross-sectional & meta-analysis	1,985	9,874
Parameswaran, Br J Dermatol. 2015 Mar; 172(3):729-38. ⁵	Identification of a new disease cluster of pemphigus vulgaris with autoimmune thyroid disease, rheumatoid arthritis, and type I diabetes*	Global (primarily United States)	Cross-sectional & meta-analysis	230	General population statistics (Center for Disease Control and Prevention)

**Figure 1** Forest plot representing the association between pemphigus and systemic lupus erythematosus (p = 0.03).

Financial support

None declared.

Authors' contributions

Vignesh Ramachandran: Approval of the final version of the manuscript; study conception and planning; preparation and writing of the manuscript; data collection, analysis, and interpretation; effective participation in research orientation; critical review of the literature; critical review of the manuscript.

Kevin Phan: Statistical analysis; approval of the final version of the manuscript; study conception and planning; data collection, analysis, and interpretation; effective participation in research orientation; critical review of the literature; critical review of the manuscript.

Saxon D. Smith: Approval of the final version of the manuscript; study conception and planning; preparation and writing of the manuscript; effective participation in research orientation; critical review of the manuscript.


Conflicts of interest

None declared.

References

- Rees F, Doherty M, Grainge MJ, Lanyon P, Zhang W. The world-wide incidence and prevalence of systemic lupus erythematosus: a systematic review of epidemiological studies. *Rheumatology (Oxford)*. 2017;56:1945–61.
- Chiu YW, Chen YD, Hua TC, Wu CH, Liu HN, Chang YT. Comorbid autoimmune diseases in patients with pemphigus: a nationwide case-control study in Taiwan. *Eur J Dermatol*. 2017;27:375–81.
- Hsu DY, Brieva J, Sinha AA, Langan SM, Silverberg JI. Comorbidities and inpatient mortality for pemphigus in the U.S.A. *Br J Dermatol*. 2016;174:1290–8.
- Kridin K, Zelber-Sagi S, Comaneshter D, Cohen AD. Association between pemphigus and psoriasis: A population-based large-scale study. *J Am Acad Dermatol*. 2017;77:1174–5.
- Parameswaran A, Attwood K, Sato R, Seiffert-Sinha K, Sinha AA. Identification of a new disease cluster of pemphigus vulgaris with autoimmune thyroid disease, rheumatoid arthritis and type I diabetes. *Br J Dermatol*. 2015;172:729–38.

6. Senear FE, Usher B. An unusual type of pemphigus combining features of lupus erythematosus. *Arch Dermatol.* 1926;13:761–81.
7. Ghandi N, Kamyab K, Attar SNG, Ghiasi M, Daneshpazhooh M, Karbaksh M, et al. Antinuclear antibody in patients with pemphigus vulgaris: a case-control study. *Br J Dermatol.* 2012;167:107.
8. Sezin T, Vorobyev A, Sadik CD, Zillikens D, Gupta Y, Ludwig RJ. Gene expression analysis reveals novel shared gene signatures and candidate molecular mechanisms between pemphigus and systemic lupus erythematosus in CD4(+) T cells. *Front Immunol.* 2018;8:1992.
9. Vanderlugt CL, Miller SD. Epitope spreading in immune-mediated diseases: implications for immunotherapy. *Nat Rev Immunol.* 2002;2:85–95.

Vignesh Ramachandran ^{a,*}, Kevin Phan ^{b,c},
Saxon D. Smith ^d

^a Department of Dermatology, Baylor College of Medicine, Houston, Texas, United States

^b Department of Dermatology, Liverpool Hospital, Sydney, Australia

^c University of New, South Wales, Sydney, Australia

^d Department of Dermatology, The Dermatology & Skin Cancer Centre, Sydney, Australia

*Corresponding author.

E-mail address: vig.ramachandran@gmail.com (V. Ramachandran).

Received 7 February 2020; accepted 23 July 2020

Available online 1 February 2021

<https://doi.org/10.1016/j.abd.2020.07.009>

0365-0596/ © 2021 Sociedade Brasileira de Dermatologia.

Published by Elsevier España, S.L.U. This is an open access article under the CC BY license (<http://creativecommons.org/licenses/by/4.0/>).

Clinical and laboratory profile of urban sporotrichosis in a tertiary hospital in the city of São Paulo^{☆,☆☆}



Dear editor,

Sporotrichosis is the most frequent subcutaneous mycosis in Latin America, where it is considered endemic.¹ At the end of the 20th century, the first cases of zoonotic transmission were described in Rio de Janeiro, initiating an epidemic outbreak that extended to other regions of Brazil.^{2–4} The lack of notification of this disease hides its real scope in the country, a fact also observed in its most populous city, São Paulo.^{5,6} This study presents clinical and laboratory data of sporotrichosis cases treated at a tertiary hospital in downtown São Paulo from 2012 to 2020, aiming to increase the knowledge of this disease. This was a retrospective study analyzing data from medical records of patients attended at the dermatology clinic of that hospital. In each case, patient characteristics (age, sex, comorbidities, and contact with a diseased animal), disease characteristics (location, time of disease, clinical form, and treatment), and diagnostic methods (direct mycological examination [DME], fungal culture [FC], and histopathological examination [HE]) were evaluated.

During the analyzed period, 20 patients were treated, with age ranging from 2 to 81 years (mean of 32.2 ± 25.10 years), 55% female and 45% male. As for zoonotic screening, 30% denied contact with an animal and 70% declared previous contact with a sick cat; no other animals were mentioned. The results obtained are described in Table 1.

Regarding the characteristics of the disease, lesions were present from three to 167 weeks until the appointment with

the dermatologist, with a mean of 20.85 ± 36.24 weeks. The limbs were the most affected sites, totaling 15 cases (75%), with two cases of upper and lower limb concomitance and two cases of limbs and face, which was the second most affected site (six patients; 30%). The lymphocutaneous form was the most frequent (50% of cases; 10 patients), followed by multiple-inoculation in five cases (25%), and fixed-cutaneous in three cases (15%); two patients presented the ocular-mucosal form and one, the immunoreactive (erythema nodosum; Fig. 1). It is interesting to note that the majority of cases (60%) were patients in the extremes of the age scale, corresponding to the population with greater contact with sick animals, a finding compatible with that described in the literature; furthermore, the fact that all patients with facial involvement were children indicates the close facial contact that patients of this age group maintain with the animal.⁷ The lymphocutaneous form is the main clinical manifestation of sporotrichosis, representing 80% of reported cases.^{2,4} In the present study, this form was the main clinical manifestation; however, it was observed in only half of the registered cases. The other half of cases presented the other manifestations, indicating that presentations described as atypical may represent a greater proportion than expected. Another noteworthy fact was that the patients' comorbidities did not indicate states of intense immunosuppression, explaining the presence of exclusively cutaneous clinical forms, without any case of systemic involvement.

For diagnostic confirmation, lesion scrapings were performed in all cases for DME and FC analysis; in 16 cases, a biopsy was also performed for HE and FC analysis. Biopsy was not performed in four cases due to the refusal of patients or guardians. HE was analyzed with hematoxylin-eosin, Grocott-Gomori, and PAS stains; the fungus was detected in only five (31.25%), similarly to review studies that report positivity between 18% and 35.3% of the cases.⁴ The presence of yeasts was not found in any DME as expected, since the test has low sensitivity and specificity when compared with culture.^{4,8} In the scraping and biopsy fragment cultures grown on Sabouraud and Mycosel agar, the fungus *Sporothrix* sp. was isolated in 100% of cases. Thus, it is confirmed

[☆] How to cite this article: Veasey JV, Neves Neto MF, Ruiz LRB, Zaitz C. Clinical and laboratory profile of urban sporotrichosis in a tertiary hospital in the city of São Paulo. *An Bras Dermatol.* 2021;96:245–8.

^{☆☆} Study conducted at the Dermatology Clinic, Hospital da Santa Casa de Misericórdia de São Paulo, São Paulo, SP, Brazil.