

2. Reinehr CPH, Bakos RM. Actinic keratoses: review of clinical, dermoscopic and therapeutic aspects. *An Bras Dermatol.* 2019;94:637–57.
3. Torezan LA, Festa-Neto C. Cutaneous field cancerization: clinical, histopathological, and therapeutic aspects. *An Bras Dermatol.* 2013;88:775–86.
4. Segatto MM, Dornelles SI, Silveira VB, Frantz GO. Comparative study of actinic keratosis treatment with 3% diclofenac sodium and 5% 5-fluorouracil. *An Bras Dermatol.* 2013;88:732–8.
5. Chen AC, Martin AJ, Choy B, Fernandez-Penas P, Dalziel RA, McKenzie CA, et al. A phase 3 randomized trial of nicotinamide for skin-cancer chemoprevention. *N Engl J Med.* 2015;373:1618–26.
6. Guimaraes CO, Bagatin E, Guadanhim LR, Sternberg F, Picosse FR, Nunes G, et al. Development and validation of a clinical scale for the evaluation of forearm skin photoaging. *J Cutan Med Surg.* 2015;19:380–7.
7. Weinstock MA, Thwin SS, Siegel JA, Marcolivio K, Means AD, Leader NF, et al. Veterans Affairs Keratinocyte Carcinoma Chemoprevention Trial (VAKCC) Group. Chemoprevention of Basal and Squamous Cell Carcinoma With a Single Course of Fluorouracil, 5% Cream. *JAMA Dermatol.* 2018;154:167–74.
8. Jury CS, Ramraka-Jones VS, Gudy V, Gerd RM. A randomized trial of topical 5% 5-fluorouracil (Efurix cream) in the treatment of actinic keratoses comparing daily with weekly treatment. *Br J Dermatol.* 2005;153:808–10.
9. Khallaf HHA, HE M, Wittenauer A, Woolley EE, Cunto M, Pervaiz MA. An incidental case of dihydropyrimidine dehydrogenase deficiency: One case, multiple challenges. *Indian J Hum Genet.* 2013;19:483–6.
10. Marinescu A, Stepan AE, Margaritescu C, Marinescu AM, Zăvoi RE, Simionescu CE, et al. P53, p16 and Ki67 immunoreexpression in cutaneous squamous cell carcinoma and its precursor lesions. *Rom J Morphol Embryol.* 2016;57:691–6.

Eliane Roio Ferreira , Anna Carolina Miola *,
Thania Rios Rossi Lima , Juliano Vilaverde Schmitt ,
Luciana Patricia Fernandes Abbade ,
Hélio Amante Miot 

*Department of Dermatology, Faculty of Medicine,
Universidade Estadual Paulista, São Paulo, SP, Brazil*

* Corresponding author.

E-mail: anna.c.miola@unesp.br (A.C. Miola).

Received 16 June 2020; accepted 14 September 2020; Available online 10 September 2021

<https://doi.org/10.1016/j.abd.2020.09.012>
0365-0596/ © 2021 Sociedade Brasileira de Dermatologia.
Published by Elsevier España, S.L.U. This is an open access article under the CC BY license (<http://creativecommons.org/licenses/by/4.0/>).

104-week safety and effectiveness of dupilumab in the treatment of severe atopic dermatitis. The experience of 5 reference dermatology units in Spain ^{☆,☆☆}



Dear Editor,

Atopic Dermatitis (AD) is a multifactorial disease resulting from the interaction of genetic predisposition, environmental triggers, disruption of skin barrier function, and type 2 immune dysregulation. Management of mild forms of AD includes the use of emollients, topical corticosteroids or calcineurin inhibitors, and phototherapy, while systemic immunosuppressive agents such as oral corticosteroids and Cyclosporine A (CsA) are reserved for severe refractory cases.¹ Nevertheless, severe cases are usually not adequately controlled with any of these therapies, requiring a further step to reach clinical control.² Recently, FDA and EMA have authorized Dupilumab, a treatment targeting Th2 cytokines IL-4 and IL-13 which has shown to be effective to control the signs and symptoms of AD. Real-world experience

with Dupilumab shows a similar effectivity as compared to randomized clinical trials, but it is yet to know how this drug will perform in the long term in routine medical practice.^{3–5}

We performed a retrospective chart review of 30 patients from 5 Andalusian reference dermatology units (Hospital Virgen del Rocío-Sevilla; Hospital Juan Ramon Jimenez-Huelva; Hospital Universitario de Puerto Real-Cádiz; Hospital Reina Sofía-Córdoba and Hospital Universitario San Cecilio-Granada) included in the Spanish compassionate use of Dupilumab for adult patients with moderate to severe AD from November 2017 to February 2020. According to the compassionate use program recommendations for dupilumab prescription, inclusion criteria were age ≥ 18 years, a severe disease defined by a baseline Eczema Area and Severity Index (EASI) ≥ 16 , and inadequate response/intolerance to CsA or medical inadvisability of CsA treatment. Patients with any documented psychiatric comorbidity were excluded from the study.

All patients were treated with subcutaneous dupilumab 300 mg every other week following a loading dose of dupilumab 600 mg. Concomitant topical corticosteroids or calcineurin inhibitors were allowed. All patients agreed with the treatment regimen and signed a written consent form to extract relevant data from their charts. Data collected included age, disease course, personal history (including comorbidities), and previous systemic/biological treatments. Disease severity was measured by Scoring Atopic Dermatitis (SCORAD) and Pruritus Visual Analog Scale (VAS) scores at the baseline visit, and at follow-up weeks 4, 12, 24, 52, 76, and 104. Quality of life was assessed with Dermatology Life Quality Index (DLQI).

[☆] How to cite this article: Pereyra-Rodriguez JJ, Dominguez-Cruz J, Armario-Hita JC, Villaverde RR. 104-week safety and effectiveness of dupilumab in the treatment of severe atopic dermatitis. The experience of 5 reference dermatology units in Spain. *An Bras Dermatol.* 2021;96:787–90.

^{☆☆} Study conducted at the Hospital Universitario San Cecilio, Granada, Spain.

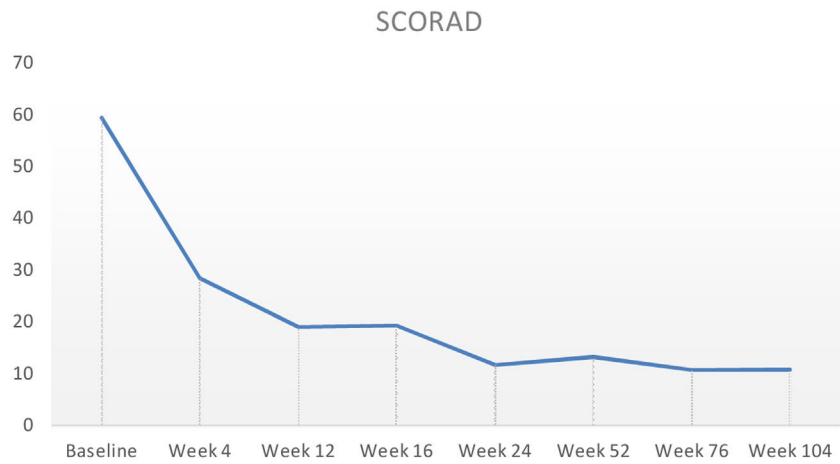


Figure 1 Mean percentage change in Scoring Atopic Dermatitis (SCORAD) from baseline through week 104 in patients treated with dupilumab.

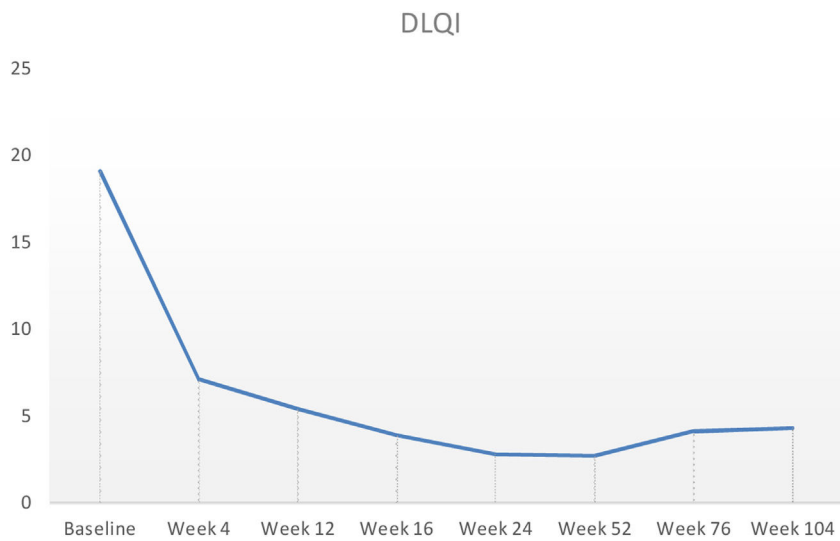


Figure 2 DLQI from baseline through week 104. DLQI, dermatology life quality index.

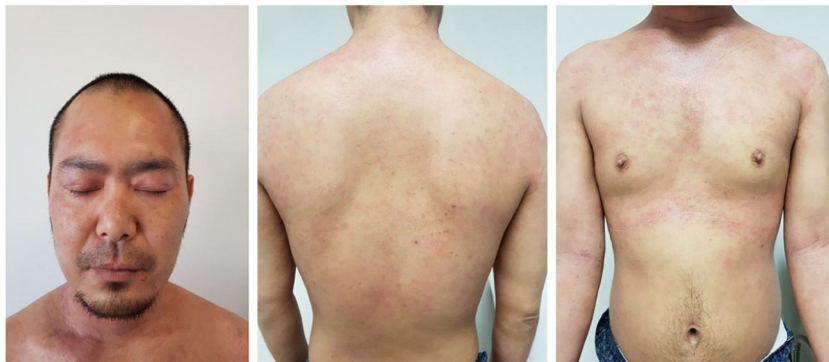

Figure 3 Baseline state on one patient in our series (SCORAD 64).

Baseline characteristics are shown in [Table 1](#). The studied population presented a substantial burden of disease, with an average of 25.7 years of AD evolution. The most

common comorbidities were allergic rhinitis (55.5%), asthma (37%), and conjunctivitis (33.4%). These comorbidities were more common in those patients with longer treatment

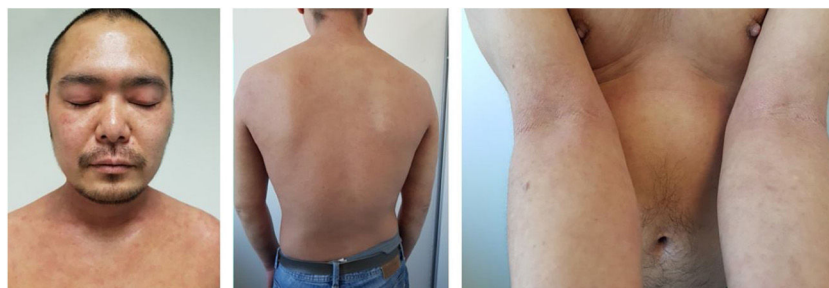

Figure 4 16w after Dupilumab treatment (SCORAD 16).

Table 1 Patients' baseline characteristics.

Characteristic	Average
Age, years (range)	40.4 (19–56)
Sex (male, %)	70% (21/30)
Years of AD evolution, years (range)	28.5 (10–44)
Comorbidities (%)	
Nasal polyps	16.6%
Conjunctivitis	36.8%
Extrinsic asthma	22.2%
Allergic rhinitis	50%
Alimentary allergies	22.2%
Previous treatment	
Oral systemic corticosteroids	100% (Average length: 23.7 months)
Oral cyclosporine	94.4% (Average's lengths: 19.8 months)
Phototherapy (NB-UVB)	33.3%
Baseline SCORAD	59.4%
Baseline pruritus VAS	8.3%
Baseline DLQI	19

with immunosuppressants. All patients had received previous treatment with oral corticosteroids, and 96.3% had been treated with cyclosporine.³ The effectiveness of the dupilumab treatment was assessed at weeks 4, 12, 24, 52, and 104. The mean percentage of change in SCORAD is shown in Fig. 1, while DLQI evolution is shown in Fig. 2. At baseline, SCORAD was 59.4, while pruritus VAS was 8.3. In the follow-up week 104 visit, SCORAD decreased to 10.7 (-82%), and pruritus VAS reduced to 2.9 (-65%). Regarding QoL, the baseline DLQI value was 19, reaching 4.3 (-77.4%) at the same cut-off. The safety profile was favorable, reporting 3 cases of mild conjunctivitis, managed positively without suspension of Dupilumab. One example of treatment effect is shown at baseline (Fig. 3) and 16 weeks (Fig. 4).

This retrospective multicentric study on a cohort of 30 patients with severe AD implies the longer follow-up published to date on real-life experience with dupilumab and confirms the efficacy of this agent for refractory cases. A statistically significant reduction in SCORAD was achieved at week 4 and maintained through week 104. The clinical improvement was accompanied by a considerable amelioration of quality of life, as measured by DLQI, and the most bothersome symptom, itch, assessed with pruritus VAS. Dupilumab was well tolerated in most patients, with only 10% of patients suffering from conjunctivitis. These results

are aligned with what was recorded in Clinical Trials but contrast with other real-world studies reporting eye symptoms in up to 62% of cases.⁵ From our experience, the use of lipid emulsion eye drops combined with hyaluronic acid eye drops as a prophylactic measure may have a protective effect against dry eyes and eye pruritus, which may have a key role in the development of conjunctivitis. Injection-site reactions were not reported by our patients. Limitations of the study are its retrospective nature and the small sample size.

To sum up, our real-life study confirmed that dupilumab is an effective treatment in patients with severe AD and provides the longest follow-up published to date.

Financial support

None declared.

Author's contributions

Jose Juan Pereyra-Rodriguez: Acquisition of data; editing; study concept and design; writing; critical review.

Javier Dominguez-Cruz: Acquisition of data; editing; design; critical review.

Jose Carlos Armario-Hita: Acquisition of data; editing; design; critical review.

Ricardo Ruiz Villaverde: Acquisition of data; editing; study concept and design; writing; critical review.

Conflicts of interest





None declared.

References

1. Silvestre Salvador JF, Romero-Pérez D, Encabo-Durán B. Atopic dermatitis in adults: a diagnostic challenge. *J Investig Allergol Clin Immunol.* 2017;27:78–88.
2. Serra-Baldrich E, de Frutos JO, Jáuregui I, Armario-Hita JC, Silvestre JF, Herraiz L, et al. Changing perspectives in atopic dermatitis. *Allergol Immunopathol.* 2018;46:397–412.
3. Ruiz-Villaverde R, Dominguez-Cruz J, Armario-Hita JC, Martinez-Pilar L, Alcantara-Luna S, Pereyra-Rodriguez JJ. Dupilumab: short-term effectiveness and security in real clinical practice – A retrospective multicentric study. *J Eur Acad Dermatol Venereol.* 2019;33:e21–2.
4. Armario-Hita JC, Pereyra-Rodriguez J, Silvestre JF, Ruiz-Villaverde R, Valero A, Izu-Belloso R, et al. Treatment of

moderate-to-severe atopic dermatitis with dupilumab in real clinical practice: a multicentre, retrospective case series. *Br J Dermatol.* 2019;181:1072–4.

5. Ferrucci S, Casazza G, Angileri L, Tavecchio S, Germiniasi F, Berti E, et al. Clinical Response and Quality of Life in Patients with Severe Atopic Dermatitis Treated with Dupilumab: A Single-Center Real-Life Experience. *J Clin Med.* 2020;9:791.

Jose Juan Pereyra-Rodriguez ^a,
Javier Dominguez-Cruz ^a, Jose Carlos Armario-Hita ^b,
Ricardo Ruiz-Villaverde ^{c,*}

^a *Dermatology Unit, Hospital Universitario Virgen del Rocío, Sevilla, Spain*

^b *Dermatology Unit, Hospital Universitario Puerto Real, Cádiz, Spain*

^c *Dermatology Unit, Hospital Universitario San Cecilio, Granada, Spain*

* Corresponding author.

E-mail: ricardo.ruiz.villaverde.sspa@juntadeandalucia.es (R. Ruiz-Villaverde).

Received 20 April 2020; accepted 24 August 2020; Available online 27 September 2021

<https://doi.org/10.1016/j.abd.2020.08.030>
0365-0596/ © 2021 Sociedade Brasileira de Dermatologia.

Published by Elsevier España, S.L.U. This is an open access article under the CC BY license (<http://creativecommons.org/licenses/by/4.0/>).