

lent result and no side effects, with complete regression of the lesion after 10 weeks of imiquimod use.<sup>10</sup>

Finally, it is important to emphasize that lesions with unusual presentations can make the diagnosis of HSV difficult. The main therapeutic regimen remains the use of acyclovir, but in patients with immunodeficiency, the association of the antiviral and the topical use of imiquimod has shown good results. Although further studies are still required, the case reported herein may help to support the use of imiquimod as a promising drug in the treatment of genital infections caused by HSV refractory to the traditional therapy.

### Financial support

None declared.

### Authors' contributions

Suellen Ramos de Oliveira: Concepts; design; definition of intellectual content; literature search; clinical studies; data acquisition; data analysis; manuscript preparation; manuscript editing; manuscript review; guarantor.

Ariane Sponchiado Assoni: Concepts; design; definition of intellectual content; literature search; clinical studies; data acquisition; manuscript preparation; manuscript editing; guarantor.

Thiago Jeunon de Sousa Vargas: Concepts; design; definition of intellectual content; clinical studies; data analysis; manuscript review; guarantor.

Egon Daxbacher: Concepts; design; definition of intellectual content; clinical studies; data analysis; manuscript review; guarantor.





### Conflicts of interest

None declared.

### References

1. Tandon S, Singh J, Sinha S, Sharma DP. Recalcitrant hypertrophic herpes genitalis in HIV-infected patient successfully treated with topical imiquimod. *Dermatol Ther*. 2017;30.

2. Perkins N, Nisbet M, Thomas M. Topical imiquimod treatment of aciclovir-resistant herpes simplex disease: case series and literature review. *Sex Transm Infect*. 2011;87:292–5.
3. Wagstaff AJ, Perry CM. Topical imiquimod: a review of its use in the management of anogenital warts, actinic keratoses, basal cell carcinoma and other skin lesions. *Drugs*. 2007;67:2187–210.
4. Deza G, Martin-Ezquerro G, Curto-Barredo L, García JV, Pujol RM. Successful treatment of hypertrophic herpes simplex genitalis in HIV-infected patient with topical imiquimod. *J Dermatol*. 2015;42:1176–8.
5. Danielsen AG, Petersen CS, Iversen J. Chronic erosive herpes simplex virus infection of the penis in a human immunodeficiency virus-positive man, treated with imiquimod and famciclovir. *Br J Dermatol*. 2002;147:1034–6.
6. Barbosa LN, Souto R, Furtado AL, Gripp AC, Daxbacher E. Association of oral acyclovir and imiquimod for the treatment of hypertrophic genital herpes simplex in HIV positive patients: report of two cases. *An Bras Dermatol*. 2011;86:1043–5.
7. Abbo L, Vincek V, Dickinson G, Shrestha N, Doblecki S, Haslett PAJ. Selective defect in plasmacytoid dendritic cell function in a patient with AIDS-associated atypical genital herpes simplex vegetans treated with imiquimod. *Clin Infect Dis*. 2007;44:25–7.
8. Camasmie HR, Barbosa C, Lupi O, Lima RB, Serra M, D'Acri AM, et al. Extensive and refractory genital herpes in human immunodeficiency virus-infected patient successfully treated with imiquimod: case report and literature review. *Indian J Dermatol Venereol Leprol*. 2017;83:256–9.
9. Scieux C, Bianchi A. Resistance of herpes simplex viruses to antiviral drugs. *Pathol Biol*. 1993;4:172–7.
10. Lestre SIA, João A, Carvalho C, Serrão VV. Hypertrophic perianal herpes successfully treated with imiquimod. *An Bras Dermatol*. 2011;86:1185–8.

Suellen Ramos de Oliveira \*,  
Ariane Sponchiado Assoni ,  
Thiago Jeunon de Sousa Vargas , Egon Daxbacher 

*Hospital Federal de Bonsucesso, Rio de Janeiro, RJ, Brazil*

\* Corresponding author.

*E-mail: suellenramospa.sr91@gmail.com* (S.R. Oliveira).

Received 18 August 2020; accepted 13 October 2020  
available online 14 January 2022

<https://doi.org/10.1016/j.abd.2020.10.019>  
0365-0596/ © 2021 Sociedade Brasileira de Dermatologia.  
Published by Elsevier España, S.L.U. This is an open access article under the CC BY license (<http://creativecommons.org/licenses/by/4.0/>).

## Bullous Sweet syndrome with a unique photodistributed pattern<sup>☆</sup>

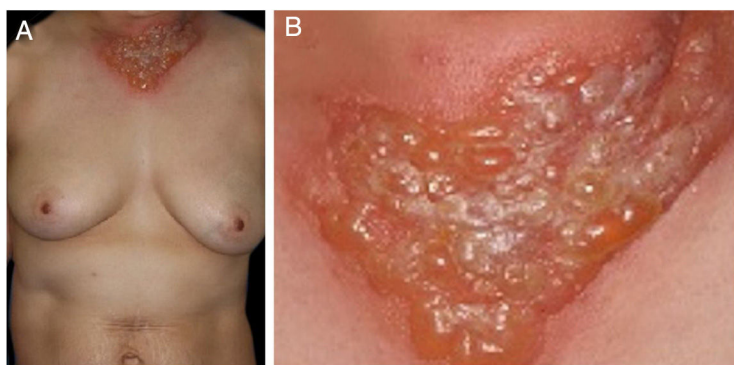


Dear Editor,

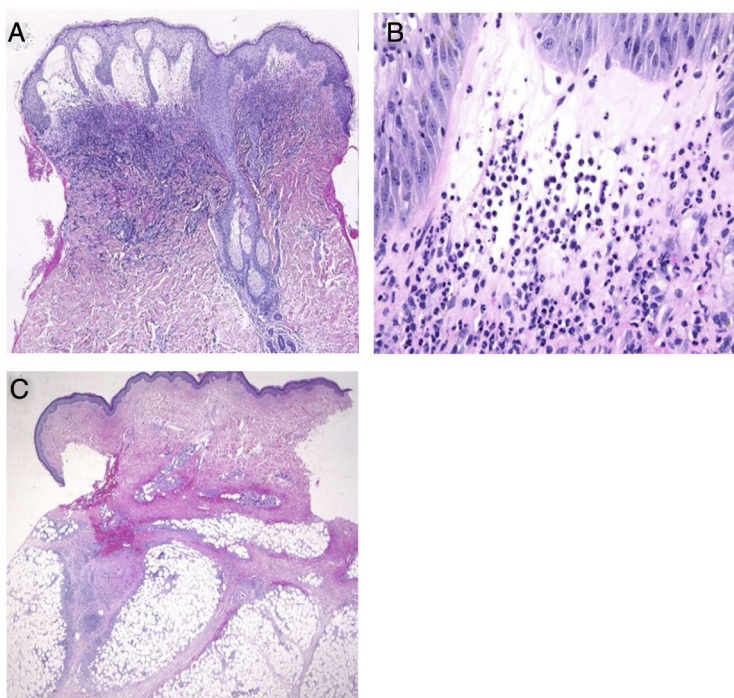
A 54-year-old female was admitted to our department, complaining of a 4-day history of up to 40.3 °C fever and cutaneous eruptions on the neck. The patient had been

suffering from myelodysplastic syndrome (MDS), for which no drugs, including granulocyte-colony stimulating factor (G-CSF), were administered. Physical examination showed numerous condescences of blisters clearly localized in the V-neck area (Fig. 1a, b). Painful erythematous nodules were scattered on the cheeks, but the tip of the nose was spared. Furthermore, there was one blister on the right forearm as well as painful erythematous nodules on the upper and lower extremities. She did not have any mucosal lesions or a prior history of recurrent oral aphthae. Laboratory examination showed a white blood cell count of 8,100/μL with 3% Band, 21% Seg, 9% Lym, 7% Mono, and 57% Blast, decreased levels

<sup>☆</sup> Study conducted at the Department of Dermatology, Fukushima Medical University School of Medicine.



**Figure 1** (A), Well-circumscribed, painful, infiltrative erythema with tense blisters in the V-neck area. (B), Close-up view.



**Figure 2** (A), Histological features showing dense neutrophilic infiltration throughout the edematous dermis (Hematoxylin & eosin, original magnification  $\times 40$ ). (B), Higher magnification showing the large number of infiltrating neutrophils (Hematoxylin & eosin,  $\times 400$ ). (C), Histological examination showing a septal panniculitis in the subcutaneous nodule in the lower extremity (Hematoxylin & eosin,  $\times 20$ ).

of hemoglobin (8.6 g/dL) and platelets (108,000/ $\mu$ L), and increased levels of C-reactive protein (26.02 mg/dL). Blood culture was sterile. A biopsy specimen from the peripheral edge of the bulla on the neck showed a subepidermal bulla and dense neutrophilic infiltration in the upper to mid-dermis (Fig. 2a, b). Immature myeloid cell infiltration was not detected. Infiltration of histiocytes/histiocytoid cells was not observed, and immunohistological examination showed scattered CD68- and MPO-positive cells which were not prominent. Additionally, another biopsy taken from the lower leg showed infiltration of inflammatory cells, mainly lymphocytes, around the vessels in the septa of the subcutaneous fat tissue (Fig. 2c). Hematological examination and bone marrow biopsy revealed transformation from MDS into acute myelocytic leukemia, and chemotherapy includ-

ing prednisolone was immediately started in the hematology department. After about one week, all of the bullous lesions were re-epithelialized.

The present case developed a sudden onset of skin lesions, which histopathologically showed a predominant neutrophilic infiltration without leukocytoclastic vasculitis. In addition, fever, elevated C-reactive protein, and rapid response to systemic steroids were observed. White blood cell count was within the upper limit of the normal range but two times higher than the usual value. Thus, the patient fulfilled the criteria for Sweet syndrome (SS). Cutaneous lesions of SS associated with myelodysplasia tend to be vesicular, bullous, or erosive. The present case developed bullous SS, simultaneously with the blastic crisis of MDS. Of interest, the lesions showed a peculiar distribution of well-

circumscribed erythema in the V-neck area not protected by clothes during the season when the dose of ultraviolet radiation is increased in Japan, which was considered to be a photo-Koebner phenomenon. Only several cases of photo-induced or photo-distributed SS have been reported, in which both ultraviolet A and ultraviolet B were candidates for induction of skin lesions.<sup>1-3</sup> Although phototesting was not performed in the present case, the patient had no previous history of photosensitive dermatitis or of taking drugs that can induce photosensitive eruptions. To our knowledge, the current report is the first case of photolocalized bullous SS. The direct action of ultraviolet is speculated to activate and recruit neutrophils via interleukin-8, tumor necrosis factor- $\alpha$ , E-selectin, interleukin-1 $\alpha$ , and G-CSF<sup>4,5</sup> as well as ultraviolet-induced local immunosuppression. Finally, the patient concurrently developed infiltrative erythematous nodules on the face and extremities. Biopsy showed septal panniculitis with lymphocytic infiltration without neutrophil infiltration in either dermis or subcutis; however, all of the concurrent lesions were considered to be part of the same spectrum.

### Financial support

None declared.

### Authors' contributions

Mai Endo: Designed the study; performed the research and contributed to analysis and interpretation of data; wrote the initial draft of the manuscript; read and approved the final version of the manuscript.

Miyuki Yamamoto: Performed the research and contributed to analysis and interpretation of data; read and approved the final version of the manuscript.

Mikio Ohtsuka: Performed the research and contributed to analysis and interpretation of data; read and approved the final version of the manuscript.





Toshiyuki Yamamoto: Designed the study; assisted in the preparation of the manuscript; read and approved the final version of the manuscript.

### Conflicts of interest

None declared.

### References

1. Horio T. Photoaggravation of acute febrile neutrophilic dermatosis Sweet's syndrome. *J Dermatol.* 1985;12:191-4.
2. Belhadjali H, Marguery MC, Lamant L, Giordano-Labadie F, Bazex J. Photosensitivity in Sweet's syndrome: two cases that were photoinduced and photoaggravated. *Br J Dermatol.* 2003;149:675-7.
3. Meyer V, Schneider SW, Bonsmann G, Beisert S. Experimentally confirmed induction of Sweet's syndrome by phototesting. *Acta Derm Venereol.* 2011;91:720-1.
4. Strickland I, Rhodes LE, Flanagan BF, Friedmann PS. TNF-alpha and IL-8 are upregulated in the epidermis of normal human skin after UVB exposure: correlation with neutrophil accumulation and E-selectin expression. *J Invest Dermatol.* 1997;108:763-8.
5. Yoshizumi M, Nakamura T, Kato M, Ishioka T, Kozawa K, Wakamatsu K, et al. Release of cytokines/chemokines and cell death in UVB-irradiated human keratinocytes, HaCaT. *Cell Biol Int.* 2008;32:1405-11.

Mai Endo \*, Miyuki Yamamoto , Mikio Ohtsuka , Toshiyuki Yamamoto 

*Department of Dermatology, Fukushima Medical University, Fukushima, Japan*

\* Corresponding author.

*E-mail:* [enmai04@fmu.ac.jp](mailto:enmai04@fmu.ac.jp) (M. Endo).

Received 20 August 2020; accepted 12 October 2020  
available online 8 February 2022

<https://doi.org/10.1016/j.abd.2020.10.018>

0365-0596/ © 2021 Sociedade Brasileira de Dermatologia.

Published by Elsevier España, S.L.U. This is an open access article under the CC BY license (<http://creativecommons.org/licenses/by/4.0/>).

## Extraocular sebaceous carcinoma: tumor presentation of rapid evolution

*Dear Editor,*

Sebaceous carcinoma (SC) is a rare malignant neoplasm derived from the adnexal epithelium of the sebaceous glands, with a higher incidence in the ocular region, particularly in the eyelid region, and has a potentially aggressive behavior.<sup>1-3</sup> Older age, previous radiotherapy, and association with Muir-Torre syndrome are predisposing conditions.<sup>1-3</sup>

This is the case report of a 75-year-old white male patient with a history of squamous cell carcinoma (SCC), referred for treatment of facial lesion noted three months before, with rapid growth and bleeding episodes associated with trauma. Upon examination, a 5-cm, rounded, erythematous-violaceous, pre-auricular tumor was observed, with friable and necrotic areas associated with a 1-cm satellite lesion with similar characteristics and a post-SCC excision skin graft scar (Fig. 1). No regional lymph node enlargement was detected. The hypotheses were SCC, SCC metastasis, and angiosarcoma. Histopathological examination (Figs. 2 and 3) showed a dermal neoplasm with polygonal clear cells, evident nuclear pleomorphism, cell debris, and frequent mitoses. Immunohistochemistry disclosed positivity for epithelial markers AE1/AE3 and epithelial membrane antigen (EMA) which, associated with histopathological findings, allowed the diagnosis of sebaceous carcinoma (SC), and

☆ Study conducted at the Department of Infectology, Dermatology, Diagnostic Imaging and Radiotherapy, Faculdade de Medicina, Universidade Estadual Paulista, Campus de Botucatu, SP, Brazil.