

Financial support

None declared.

Authors' contributions

Diego Henrique Morais Silva: Design and planning of the study; drafting and editing of the manuscript; collection, analysis, and interpretation of data; critical review of the literature.

Neusa Yuriko Sakai Valente: Approval of the final version of the manuscript; effective participation in research orientation; intellectual participation in the propaedeutic and/or therapeutic conduct of the studied cases; critical review of the manuscript.

Agatha Ramos Oppenheimer: Approval of the final version of the manuscript; critical review of the manuscript.





Anna Karoline Gouveia de Oliveira: Approval of the final version of the manuscript; critical review of the manuscript.

Conflicts of interest

None declared.

References

- Carlson JA, Chen KR. Cutaneous vasculitis update: neutrophilic muscular vessel and eosinophilic, granulomatous, and lymphocytic vasculitis syndromes. *Am J Dermatopathol*. 2007;29:32–43.
- Marquez J, Flores D, Candia L, Espinoza LR. Granulomatous vasculitis. *Curr Rheumatol Rep*. 2003;5:128–35.
- Sharma A, Dogra S, Sharma K. Granulomatous vasculitis. *Dermatol Clin*. 2015;33:475–87.
- Suwanchote S, Rachayon M, Rodsaward P, Wongpiyabororn J, Deekajorndech T, Wright HL, et al. Anti-neutrophil cytoplasmic antibodies and their clinical significance. *Clin Rheumatol*. 2018;37:875–84.
- Chen KR. Cutaneous polyarteritis nodosa: a clinical and histopathological study of 20 cases. *J Dermatol*. 1989;16:429–42.

Diego Henrique Morais Silva *,
Neusa Yuriko Sakai Valente ,
Agatha Ramos Oppenheimer ,
Anna Karoline Gouveia de Oliveira 

Department of Dermatology, Hospital do Servidor Público Estadual de São Paulo, São Paulo, SP, Brazil

* Corresponding author.

E-mail: dhenriquems@gmail.com (D.H. Silva).

Received 22 September 2020; accepted 14 October 2020
Available online 21 March 2022

<https://doi.org/10.1016/j.abd.2020.10.021>

0365-0596/ © 2022 Sociedade Brasileira de Dermatologia.

Published by Elsevier España, S.L.U. This is an open access article under the CC BY license (<http://creativecommons.org/licenses/by/4.0/>).

Therapeutic approach of Lyell syndrome with infliximab and dexamethasone pulse: report of a clinical case[☆]



Dear Editor,

Toxic Epidermal Necrolysis (TEN) is a rare, life-threatening mucocutaneous disease.

A 23-year-old female presented with TEN after treatment with diclofenac, metamizole and etoricoxib. She was febrile, with oral, ocular, and perineal mucositis and a maculopapular rash involving an estimated body surface area of 20%. She was admitted to the dermatology department, skin biopsies were collected, and Intravenous Immunoglobulin (IVIg) was started. However, her clinical condition worsened, so she was transferred to the burn unit.

Upon admission, the patient had an extensive maculopapular rash. There were also positive Nikolsky signs in her face, back, palms and feet soles, and involvement of the oral, ocular, vaginal and perineal mucous membranes (Figs. 1 and 2). Additionally, given the upper airway edema, she was orotracheal intubated.

Under immunoglobulin therapy, there was a clinical worsening, with an increase in the body surface involvement, from 85% to 100%. In addition, she developed multiorgan failure with hematological, cardiovascular, hepatic, gastrointestinal and renal dysfunction.

On the eighth day of hospitalization, the patient received a single infliximab dose (5 mg/kg, EV) and was started on a pulse of dexamethasone (100 mg, EV × 1/day) for three days. After administration of infliximab and dexamethasone pulse, the patient evolved favorably with the progressive resolution of multiorgan dysfunction, and on the nineteenth day, the patient presented epithelialization of the entire body surface.

According to literature, TEN is a severe idiosyncratic reaction, mostly drug-induced. It is characterized by a detachment of the skin and mucous membranes at the level of the dermis-epidermis junction as a result of the necrosis of keratinocytes.

The diagnosis of TEN is clinical. It is characterized by a prodromal phase with flu-like symptoms that precede the appearance of mucocutaneous lesions. The confirmation of the diagnosis involves a skin biopsy.¹

In patients with probable drug-induced TEN, early diagnosis and immediate removal of the drug are essential to improve the prognosis.

Apart from supportive care, there is no established treatment. However, several immunosuppressants and immunomodulators have been used, and although there are

[☆] Study conducted at the Hospital de Santa Maria, Centro Hospitalar Universitário Lisboa Norte, Lisboa, Portugal.

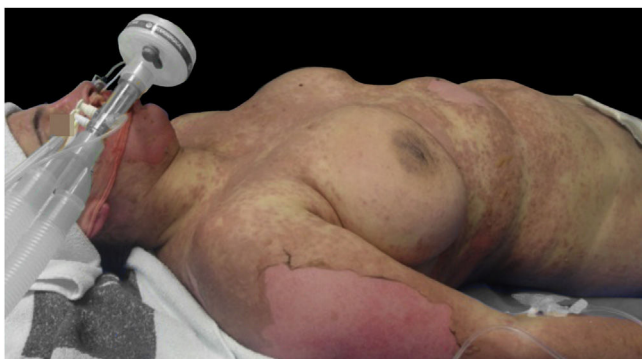

Figure 1 Blisters, vesicles, and detachment of the epidermis.

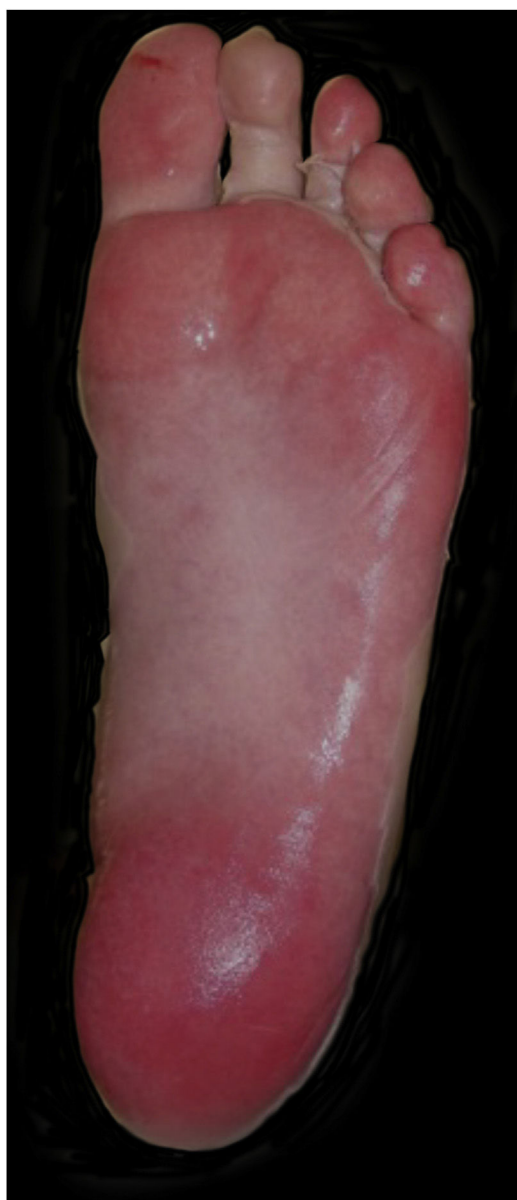

Figure 2 Detachment of the epidermis.

no adequate randomized studies, some drugs have shown promise.

Corticosteroids were among the first drugs used; however, their use is currently controversial. Although some studies demonstrate a worse prognosis,² there are others that show benefits with the administration of high doses over a short period of time.³

IVIg used to be the most consensual therapy for the treatment of this syndrome. However, a meta-analysis published in 2012 concluded that this drug is not associated with a better prognosis.⁴

TNF-alpha inhibitors seem promising drugs in the treatment of TEN. There are some case reports where a single dose of infliximab or etanercept interrupted the progression of the disease and induced regression of the skin lesions.⁵

In fact, the case we reported is in line with these findings since the patient did not show any improvement after IVIg administration but had a great response to infliximab and high-dose dexamethasone.

Financial support

None declared.

Authors' contributions

Jânia Dara Jácome Pacheco: Collection, analysis, and interpretation of data; effective participation in research orientation; intellectual participation in the propaedeutic and/or therapeutic conduct of the studied cases; management of case studies; critical review of the manuscript; drafting and editing of the manuscript; critical review of the literature.

Maria Rodrigues Viegas Ribeiro: Critical review of the literature; collection, analysis, and interpretation of data; drafting and editing of the manuscript.

Catarina Sousa Duque Soares Queirós: Critical review of the manuscript.

Maria Fátima Cameira Martins Xambre: Approval of the final version of the manuscript.





Conflicts of interest

None declared.

References

1. Cabral L, Diogo C, Riobom F, Teles L, Cruzeiro C. Toxic epidermal necrolysis (Lyell syndrome): a pathology for burn units. *Acta Med Port.* 2004;17:129–40.
2. Kelemen JJ, Cioffi WG, McManus WF, Mason AD Jr, Pruitt BA Jr. Burn center care for patients with toxic epidermal necrolysis. *J Am Coll Surg.* 1995;180:273–8.
3. Kardaun SH, Jonkman MF. Dexamethasone pulse therapy for Stevens-Johnson syndrome/toxic epidermal necrolysis. *Acta Derm Venereol.* 2007;87:144–8.
4. Huang YC, Li YC, Chen TJ. The efficacy of intravenous immunoglobulin for the treatment of toxic epidermal necrolysis: a systematic review and meta-analysis. *Br J Dermatol.* 2012;167:424–32.

5. Woolridge KF, Boler PL, Lee BD. Tumor necrosis factor alpha inhibitors in the treatment of toxic epidermal necrolysis. *Cutis*. 2018;101:E15–21.

Jânia Dara Jácome Pacheco  ^{a,*},
 Maria Rodrigues Viegas Ribeiro  ^a,
 Catarina Sousa Duque Soares Queirós  ^b,
 Maria Fátima Cameira Martins Xambre  ^a

^a Department of Anaesthesiology, Hospital de Santa Maria, Centro Hospitalar Universitário Lisboa Norte, Lisboa, Portugal

^b Department of Dermatology, Hospital de Santa Maria, Centro Hospitalar Universitário Lisboa Norte, Lisboa, Portugal

* Corresponding author.

E-mail: janja.pacheco@hotmail.com (J.D. Pacheco).

Received 30 July 2020; accepted 13 October 2020

Available online 2 April 2022

<https://doi.org/10.1016/j.abd.2020.10.020>

0365-0596/ © 2022 Sociedade Brasileira de Dermatologia.

Published by Elsevier España, S.L.U. This is an open access article under the CC BY license (<http://creativecommons.org/licenses/by/4.0/>).

Uremic stomatitis[☆]



Dear Editor,

A 42-year-old male patient was seen at the Dermatology Service due to the presence of whitish lesions on the oral mucosa, affecting mainly the tongue. Moreover, he reported significant dysgeusia and a lack of appetite. He had chronic kidney disease and had been undergoing conservative treatment so far. The examination of the oral cavity showed whitish plaques with threadlike projections adhered to the lateral borders of the tongue (Figs. 1 and 2) and a white plaque on the left cheek mucosa (Fig. 3). He had ketone breath on examination. The patient was awaiting dialysis and had a serum creatinine level of 17 mg/dL, with uremia of 200 mg/dL. After a few hemodialysis sessions, the lesions regressed significantly.

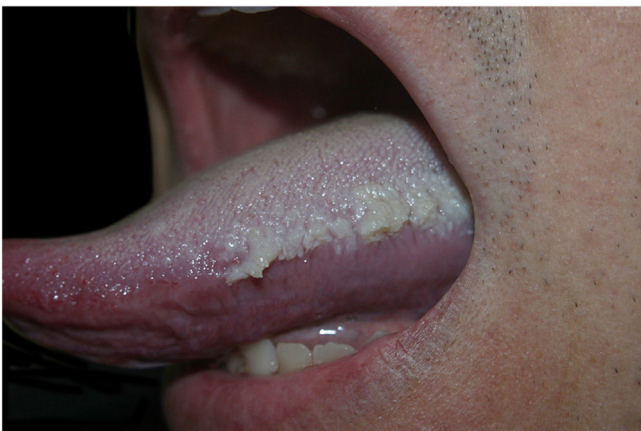

Figure 1 Whitish plaque with threadlike projections adhered to the left lateral border of the tongue.

Uremic stomatitis is an underreported disease of the oral mucosa, possibly associated with long-term uremia in patients with chronic kidney disease.¹ It was first mentioned by Lancereaux in 1887 and described by Barie in 1889 as an uncommon but characteristic complication of advanced kidney disease.² It has a low incidence² which notably decreased with the advent of dialysis, and is rarely seen nowadays.³ The etiology remains unknown, and it has been suggested that it may be due to high levels of ammonia compounds.¹ Ammonia is formed through the action of bacterial ureases that modify salivary urea, which is elevated in renal patients. The clinical characteristics are poorly defined and are rarely detailed in publications.¹ The affected patients may complain of pain, dysgeusia, and a burning sensation.^{1,4} Four clinical types of uremic stomatitis have been described: pseudomembranous, ulcerative, hemorrhagic, and hyperkeratotic.² The ulcerative type is the most common,² with an erythematous appearance, and the hyperkeratotic type is a rare alteration that can occur in long-term renal failure. Diagnosis is based on clinical signs and symptoms, and histopathology is characterized by epithelial hyperplasia and unusual hyperparakeratinization.^{1,5} Lichen planus, hypertrophic candidiasis, oral hairy leukoplakia, and vitamin deficiencies are important differential diagnoses.⁴ The treatment consists in improving blood urea levels.² The manifestations usually persist for two to three weeks. Hydrogen peroxide washes can contribute to the elimination of anaerobic bacteria that produce ammonia.¹ Despite the high frequency of patients with kidney disease, only a few cases of uremic stomatitis have been published. Investigations are required for a better understanding of the pathogenic mechanism of this disorder.

[☆] Study conducted at the Irmandade Santa Casa de Misericórdia de Porto Alegre, Porto Alegre, RS, Brazil.